

Unusual Presentation of Schwannoma: A Case Report and Literature Review

Christos Kakos¹, Sofoklis Mitsos¹, Nikolaos Madouros¹, Davide Patrini¹, Reena Khiroya², Elaine Borg², David Lawrence¹, Nikolaos Panagiotopoulos¹

¹ Department of Thoracic Surgery, University College London Hospitals (UCLH) NHS Foundation Trust, London, UK

² Department of Cellular Pathology, University College London Hospitals (UCLH) NHS Foundation Trust, London, UK

Received: 10 Nov. 2017; Accepted: 23 Dec. 2017

Abstract- Schwannoma is a benign encapsulated tumor of the nerve sheath. Amongst other sites, it develops in the posterior mediastinum in the costovertebral sulcus. We herein present a case of a 68-year-old woman with an incidental finding of a subcarinal mass. Radiological and histopathological studies were suggestive of schwannoma. Therefore, the mass was completely resected through a right thoracotomy, and a definite histopathological diagnosis was established. Although the subcarinal area is a rare site for this tumor to appear, the schwannoma should be considered as part of the differential diagnosis of lesions in the subcarinal region. Treatment of choice is the nerve-sparing surgical excision of the mass with excellent prognosis. A review of the literature on this topic was performed.

© 2018 Tehran University of Medical Sciences. All rights reserved.

Acta Med Iran 2018;56(10):681-683.

Keywords: Neurogenic tumor; Schwannoma; Mediastinal tumor

Introduction

Schwannoma is a benign, encapsulated tumor of the nerve sheath of the peripheral nerves. It originates from the Schwann cells and has a unique histological pattern. It is either asymptomatic or presents as a mass, which causes compressing symptoms to adjacent structures. Neurologic symptoms are rather late (1-3). We herein present a case of schwannoma in the subcarinal area, which is a rare site for this tumor to present. A review of the literature on this topic was performed.

Case Report

A 68-year-old woman presented with low back pain with radicular symptoms and a feeling of “pins and needles” on the upper limbs. There was no significant previous medical history. The MR imaging (MRI) suggested spondyloarthritis as the diagnosis and revealed an incidental finding of a posterior mediastinal mass immediately anterior to T5-T8 vertebrae. Further investigations with a CT scan and a PET/CT were done. The CT scan revealed a 3.1x3.9x5.1 cm well-defined lobulated para-oesophageal soft tissue mass in the midline displacing the middle third of the esophagus towards the left (Figure 1A). A whole body FDG-CT-PET scan showed a right, subcarinal, para-oesophageal

mass with increased focal uptake (SUV max 9.9). No FDG avid nodal disease was described in any of the stations above and below the diaphragm (Figure 1B).

An EBUS biopsy of the mass was performed. The histopathological and immunohistochemical studies were consistent with schwannoma. The decision was made to resect electively the mass via right posterolateral thoracotomy. The mass was adjacent to the esophagus, the aorta, the hemiazygos vein and the chyle duct (Figure 2). Lymph node sampling was also performed. The procedure was uncomplicated. The postoperative course was unremarkable, and the patient was discharged home on the 4th postoperative day.

The microscopic examination showed an encapsulated tumor with occasional pericapsular aggregates of lymphocytes. The tumor was composed of fascicles of spindle cells with wavy nuclei and pale eosinophilic cytoplasm. There were hypo- and hypercellular areas (Figure 3). The lymph node biopsy showed reactive changes with no evidence of malignancy. The immunohistochemistry studies showed spindle cells strongly S100 positive. Desmin, EMA, CD117, DOG1 were negative. So the diagnosis of subcarinal schwannoma was confirmed. The postoperative course was uncomplicated, and the patient was discharged within 3 days following surgery.

Corresponding Author: S. Mitsos

Department of Thoracic Surgery, University College London Hospitals (UCLH) NHS Foundation Trust, London, UK
Tel: +20 3456 6059, Fax: +20 3456 6062, E-mail address: sophocmit@yahoo.gr

Unusual presentation of schwannoma

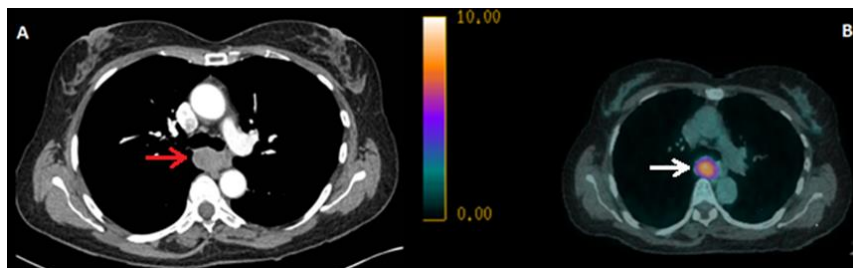


Figure 1. A) Computed Tomography (CT) scan of the chest showing a well-defined para-oesophageal mass in the posterior mediastinum and especially in the subcarinal area (red arrow) B) FDG-CT-PET scan of the chest showing an FDG avid subcarinal mass (white arrow)

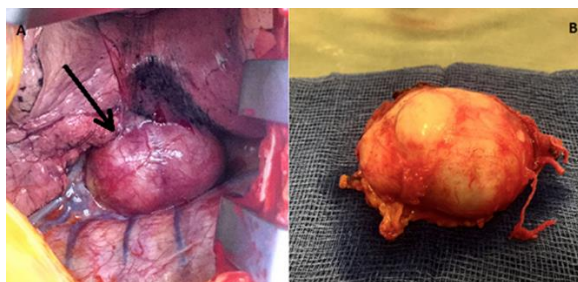


Figure 2. A) Intraoperative view of the subcarinal schwannoma (black arrow) B) Encapsulated white nodular lesion measuring 50x35x34mm

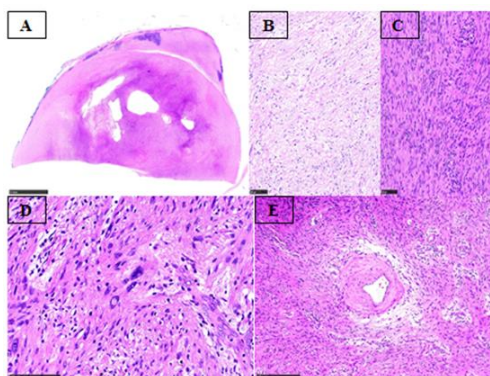


Figure 3. Schwannoma (H and E) A: Well circumscribed non encapsulated spindle cell tumour, B: hypocellular areas (H and E X 200 magnification), C: hypercellular areas (H and E X 200 Magnification), D: ancient change (H and E X300 Magnification), E: thick-walled blood vessel (H and E X100 Magnification)

Discussion

Posterior mediastinal masses are of neural origin in approximately 95 percent of patients and may arise from sympathetic ganglion cells (neuroblastoma, ganglioneuroblastoma, ganglioneuroma) or from nerve sheaths (neurofibroma, schwannoma). Rarer causes of posterior mediastinal masses include paraspinal abscess, adjacent pleural or lung mass, lymphoma, aortic aneurysm, neurenteric cyst, lateral meningocele and extramedullary hematopoiesis (1-5).

Schwannoma is the most common neurogenic tumor of the posterior mediastinum. It usually appears as a single, lobulated, encapsulated mass in the costovertebral

sulcus. Sometimes it might present as multilocular lesions and can be associated with Von Recklinghausen disease (1,3,4). It derives from the peripheral nerves and cranial nerves. Common sites of this tumor are the flexor surfaces of the extremities, head, neck, mediastinum, retroperitoneum, posterior spinal roots, and cerebellopontine angle. The origin of the mediastinal schwannoma is usually the intercostal nerves. Rarely does it originate from the vagus or the phrenic nerve (5-8)? It might rarely have malignant potential (1% progress to neurofibrosarcoma). It usually appears in patients 20-50-year-old. It equally affects men and women.

Histologically, a benign schwannoma has two distinct regions, hypercellular regions with fascicles of benign

spindle cells with wavy nuclei and pale eosinophilic cytoplasm and hypocellular areas with loose connective tissue. According to immunohistochemistry studies, the spindle cells are strongly positive for S100 protein. Malignant schwannomas show atypia, mitoses, pleomorphism and necrosis (1-3,6).

A schwannoma usually arises in the costovertebral sulcus. It can rarely be found in the subcarinal area of the posterior mediastinum as in our case. After a thorough review of the literature, only another four cases of subcarinal schwannoma have been reported (7-10). Another case report presented an esophageal schwannoma which was extending to the subcarinal area (11). Other rare sites of mediastinal schwannoma that have been described include the pre-carinal region, the aortopulmonary window, extension to the cervical region or the spinal canal (1,2,4). The patients were either asymptomatic or had symptoms due to compression of adjacent structures from the mass. The diagnosis was made by CT, MRI, PET-CT scan and EBUS biopsy. All the patients underwent either thoracotomy or video-assisted thoracoscopy or robotic-assisted thoracoscopy, and complete excision of the mass was performed. The surgical approach depends on the tumor's characteristics, location, and size. On the follow-up of the patients, there was no evidence of recurrence.

As concluded from the above, the treatment of choice for benign schwannoma is surgical excision of the mass, while attempting to spare the nerve it originates from. The recurrence is unlikely after complete resection of the mass. In the case of malignant schwannoma, en bloc resection of the mass should be performed (3,4).

Benign schwannoma in the subcarinal area is a rare and unusual presentation of posterior mediastinal schwannoma. The first line of treatment is nerve-sparing surgical resection. It has an excellent prognosis following resection and no evidence of recurrence.

Acknowledgments

Presented as a poster at the ASCVTS 2017 Seoul, Korea March 23- 26, 2017

References

1. Ciftci F, Kaya AG, Karacay E, Ciledag A, Ceyhan K, Kaya A, et al. Mediastinal Schwannoma with Atypical Localization Diagnosed by Endobronchial Ultrasound. *Clin Respir J* 2017;11:739-42.
2. Rammos KS, Rammos SK, Foroulis CN, Zaramboukas TK. Schwannoma of the vagus nerve, a rare middle mediastinal neurogenic tumor: case report. *J Cardiothorac Surg* 2009;4:68.
3. Das A, Choudhury S, Basuthakur S, Mukhopadhyay A, Mukherjee S. Massive hemoptysis: a rare presentation of posterior mediastinal, giant, benign vagal schwannoma. *Arch Iran Med* 2014;17:779-82.
4. Negri G, Bandiera A, Carretta A, Puglisi A, Mandelli C, Ciriaco P et al., Unusual Presentation of Mediastinal Neurogenic Tumours. *Case Rep Surg* 2013;2013:414260.
5. Strollo DC, Rosado-de-Christenson ML, Jett JR. Primary mediastinal tumors: part II. Tumors of the middle and posterior mediastinum. *Chest* 1997;112:1344-57.
6. Knight DM, Birch R, Pringle J. Benign solitary schwannomas: a review of 234 cases. *J Bone Joint Surg Br* 2007;89:382-7.
7. Ishibashi H, Ohta S, Hirose M, Togo T, Muro H, Nakajima N. Middle mediastinal schwannoma originating from the intrathoracic vagal nerve with difficulty in swallowing; report of a case. *Kyobu Geka* 2012;65:840-3.
8. Dahdah J, Validire P, Grigoriou M, Lenoir S, Gossot D, Stern JB. Cystic mediastinal schwannoma appended to the vagus nerve. *Rev Mal Respir* 2016;33:383-7.
9. Endo S, Murayama F, Yamaguchi T, Haseqawa T, Sohara Y, Fuse K, et al. Subcarinal neurogenic tumor: report of a case. *Surg Today* 1998;28:1307-9.
10. Odaka M, Shibasaki T, Asano H, Marushima H, Yamashita M, Morikawa T. A surgical case of subcarinal schwannoma. *Jpn J Thorac Cardiovasc Surg* 2016;30:164-8.
11. Singhal M, Misra V, Dhingra V, Misra SP. Giant cellular neurilemmoma, a rare mesenchymal tumor of the oesophagus: A case report with review of literature. *Int J Case Rep Images* 2012;3:35-8.