

# Gastrointestinal Stromal Tumor in Cardia and Small Stomach Curvature: A Case Report

Mocin Moghaddam Ahmadi, Mohammad Javad Ghanbarkhah, Hossein Mohammadi, Marzieh Gholizadeh

*Student Research Committee, Guilan University of Medical Sciences, Rasht, Iran*

*Received: 06 Mar. 2018; Accepted: 15 Dec. 2018*

**Abstract-** Gastrointestinal Stromal Tumors (GISTs) are the most common gastrointestinal mesenchymal tumors and in 80% of the cases are associated with KIT activating mutations. The incidence of GISTs is generally 10-20 cases per million population, which turn out to be malignant in 20-30% of cases. GISTs can be large and present with dysphagia, even though they are usually small and asymptomatic. A 67-year-old woman was referred to the hospital complaining of pain and burning in epigastric area and left flank; the patient had experienced a weight loss within one month before the admission. Primary investigations upon upper endoscopy revealed a submucosal mass in distal part of esophagus, and nodularity and erythema in stomach. But through more examinations by MDCT of Abdomen and Pelvis, a mass measuring 20\*33 mm in cardiac and lesser curvature submucosa, without lymphadenopathy was reported, that could suggest GIST. This mass was excised with normal margins via wide local excision, bilayer cardioplasty and funduplication. The patient was hospitalized for 10 days after surgery, and was discharged with good general condition. In follow-up, there wasn't any sign of dysphagia and dyspepsia within 24 months. In the patients suffering from GIST, the tumor location appears to have the most important role on deciding whether to perform local excision or not. Treatment of GISTs locating near gastroesophageal junction (GE junction) is still challenging. Using an appropriate therapeutic method is crucial in improving the patient's quality of life. Therefore, wide local excision followed by bilayer cardioplasty and funduplication, could be considered as the appropriate therapeutic protocol in such same situations due to elimination of post total gastrectomy adverse effects and the tumor relapse.

© 2019 Tehran University of Medical Sciences. All rights reserved.

*Acta Med Iran* 2019;57(2):138-140.

**Keywords:** Gastrointestinal stromal tumors; Gastroesophageal junction; Wide local excision; Bilayer cardioplasty; Funduplication

## Introduction

Gastrointestinal Stromal Tumors (GISTs) are the most common gastrointestinal mesenchymal tumors (1). The pathogenicity and the molecular basis of GIST have recently been recognized, which is related to the KIT activating mutations in 80% of cases (2). The incidence of GIST is generally 10-20 cases per million Population, which are malignant in 20-30% of cases. These tumors are often seen in people over the age of 50 years and are uncommon before the age of 40 and very rare in children (3). GISTs have the highest prevalence in the stomach (60%), small intestine (30%), and esophagus (1%) (4). Esophageal GIST is a rare disease, so data and information is limited about it. Esophageal GIST occurs usually in distal third part of esophagus and generally is

small and symptomless; but it also can be large with dysphagia presentation (5).

The most important differential diagnosis of esophageal GIST is leiomyoma. This distinction is very important because esophageal GIST tends to cause malignancy and invasion, while the leiomyoma is quite benign (6). Stomach GIST has an intraluminal or exophytic pattern of growth into the lumen or peritoneum but the risk of its invasion or recurrence is different (7), it also can grow in cardia (8), that could be confused with esophageal GIST; which is important to be differentiated from.

In this report, a 67-year-old female was firstly checked out based on the diagnosis of esophageal GIST and nodularity and erythema in stomach, but then it was found that the disease has involved cardia with origination of lesser curvature of stomach. Our therapeutic approach

**Corresponding Author:** M.J. Ghanbarkhah

Student Research Committee, Guilan University of Medical Sciences, Rasht, Iran

Tel: +98 13 33330941, Fax: +98 13 33330941, E-mail address: Javad.ghanbarkhah98@gmail.com

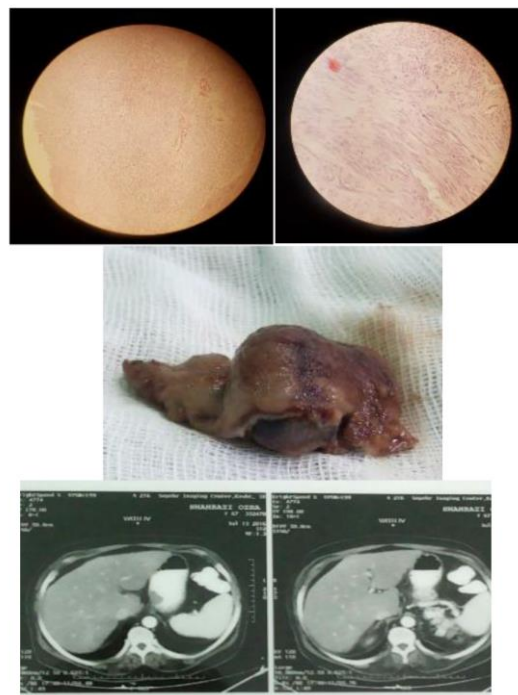
was wide local excision with preservation of stomach that has been done without causing dysphagia or other problems in patient so far; thus, this protocol can be used in the same situations.

## Case Report

A 67-year-old female was presented to the hospital complaining from pain and burning sensation in epigastric and left flank regions that had been started since a few months before admission. It was a continuous and non-positional pain, exacerbated by feeding and non-relevant to defecation. In addition to dyspepsia, patient was suffering from bloating, gastric reflux, weight loss (about 2kg during one month before the admission). She was using omeprazole daily in order to relieve her heartburn. She had a history of hypertension and hypothyroidism during 10 years ago and diabetes mellitus and also had a familial history of gastric cancer in her father and prostatic cancer in her brother. Primary investigations through upper GI endoscopy has discovered a submucosal mass measured 15\*20 mm in diameter at distal part of esophagus and antral erythema and nodularity in stomach. Biopsy from distal esophageal and gastric antral mucosa was shown a cardiac-oxynitic mucosa and chronic gastritis with *H. pylori* microorganism but it didn't show any atrophy, metaplasia or dysplasia. EUS has reported a hypoechoic lesion with regular borders originated from muscularis propria without LAP; the adjacent organs were normal on EUS. Spiral MDCT of pelvis and abdomen reported a 30\*22mm lobulated hypodense lesion in submucosal aspect of cardia in lesser curvature of stomach without surrounding invasion or lymphadenopathy. Examinations through EUS and MDCT revealed that the probable type of the tumor could be GIST as the first differential diagnosis (Figure 1).

The patient underwent surgery. It was done under supine position and with an abdominal midline incision; and gastric GIST in lesser curvature of stomach with distal esophageal and cardiac involvement, has been resected via wide local excision with healthy margins. Esophagogastrotomy had been done by means of bilayer cardioplasty and fundoplication. Meanwhile, pyloroplasty had been performed due to local vagotomy. In pathology, IHC tests have been fulfilled on the specimen resected during the surgery for differentiating GIST from leiomyoma, in which c-Kit (CD117) and CD34 were positive and S100P and Smooth muscle actin were negative. Due to the patient's symptoms and paraclinical findings, GIST with probable distal esophageal

origination was considered as the diagnosis. Margins were negative for tumor involvement and the tumor was considered low-risk from histologic aspects. The patient was hospitalized for 10 days after surgery, and was discharged with good general condition. In follow-up, she hadn't experience dysphagia and dyspepsia within 24 months.



**Figure 1.** Spiral MDCT of pelvis and abdomen reported a 30\*22mm lobulated hypodense lesion in the submucosal aspect of cardia in the lesser curvature of the stomach without surrounding invasion or lymphadenopathy

Histology slide from the biopsy taken from the distal part of esophagus. (\*10 view on the left side and \*40 on the right side)

## Discussion

In this case, the primary investigations were performed based on endoscopic and radiologic findings. On the endoscopic studies, a mass was seen in the distal portion of esophagus as submucosal changes. On EUS, there were two hypoechoic lesions originating from muscularis propria with well-defined borders, proposing an esophageal GIST. More over, a 30\*22 mm lobulated hypodense lesion in the submucosal layer of cardia without surrounding invasion or LAP was found on spiral MDCT; ruling out esophageal SCC and adenocarcinoma, because these two conditions are accompanied with more cellular infiltration and lymphatic invasion. In order to differentiate GIST from leiomyoma, IHC tests were performed. IHC

tests showed CD117 (the most sensitive marker) and CD34 expression, indicative of gastric GIST in lesser curvature with distal esophageal and cardiac involvement.

Although a simple resection appears feasible in most cases; in some cases, tumor size and location may dictate a more expensive surgery, including partial or total gastrectomy. So, the extent of surgery should be determined after considering the tumor size, location and relationship with adjacent organs to achieve a complete resection (9). It was mentioned in another research that the tumor location appears to have the most important role in deciding whether to perform local excision or not (10). Submucosal tumors adjacent to gastroesophageal junction (GE junction) or pylorus are sometimes difficult to be removed by simple wedge resection and may need distal gastrectomy or proximal gastrectomy, which can cause post gastrectomy functional sequelae; thus the treatment of GISTs locating next to GE junction is still very challenging. (11).

In conditions similar to this case, due to involvement of lesser curvature, distal esophagus, and cardia, most surgeons prefer total gastrectomy surgery with following resection of the distal esophagus and local reconstruction surgery; which are costly and extensive surgeries accompanying several side effects like distal esophageal stenosis, anastomosis site leakage and damage to vagus nerve and the adjacent vessels. Because of these sequelae, we decided to resect the tumor via wide local excision throughout the operation. Tumor resection was then followed by distal esophageal reconstruction, bilayer cardioplasty and funduplication. Therefore, the stomach was preserved and the recovery was resulted with the least complications. The patient was discharged with good general condition. Although a study has shown that overall survival in the patients undergoing incomplete tumor resection is 3 times less than the patients with a total tumor resection plan (22 against 66 months) (12), in our study there was no sign of relapse during 24 months follow up. The patient was informed consent for her inclusion in the case report and there was no conflict of interests.

In the patients suffering from GIST, the tumor location appears to have the most important role on deciding whether to perform local excision or not. Treatment of GIST next to gastroesophageal junction (GE junction) is still challenging. Using an appropriate therapeutic method is crucial in improving the patient's quality of life; therefore, Wide local excision with bilayer cardioplasty and funduplication, could be considered as the appropriate therapeutic protocol in such same situations due to elimination of its adverse effects and the tumor

relapse. As well, this case is reported to raise the awareness of the clinicians facing this kind of rare cases.

## References

1. Shinagare A, Zukotynski K, Krajewski K, Jagannathan J, Butrynski J, Hornick J, et al. Esophageal gastrointestinal stromal tumor: report of 7 patients. *Cancer Imaging* 2012;12:100-6.
2. Bagheri R, Gh M, Tavasoli A. Esophagogastricmesenchymal tumors: analysis of 24 patients. *Tehran Univ Med Sci* 2011;69:26469-72.
3. Kafeel M, Cheedella N, Wang J. Esophageal gastrointestinal stromal tumors presenting as mediastinal mass. *Case Rep Oncol* 2013;6:579-84.
4. Sjogren PP, Banerji N, Batts KP, Graczyk MJ, Dunn DH. Rare presentation of a gastrointestinal stromal tumor with spontaneous esophageal perforation: a case report. *Int J Surg Case Rep* 2013;4:636-9.
5. Gh M. Esophageal leiomyomatosis in a 70-year-old man: a case report. *Tehran Univ Med J Publ* 2008;66:437-40.
6. Simoglou C, Mikroulis D, Konstantinou F, Bougioukas G. Giant 10 cm Diameter Esophageal Gastrointestinal Stromal Tumor (GIST). *World J Cardiovasc Surg* 2014;4:177.
7. Vicente E, Quijano Y, Ielpo B, Duran H, Diaz E, Fabra I, et al. Robot-assisted resection of gastrointestinal stromal tumors (GIST): a single center case series and literature review. *Int J Med Robot* 2016;12:718-23.
8. Kang HC, Menias CO, Gaballah AH, Shroff S, Taggart MW, Garg N, et al. Beyond the GIST: mesenchymal tumors of the stomach. *Radiographics* 2013;33:1673-90.
9. El-Hanafy E, El-Hemaly M, Hamdy E, Abd El-Raouf A, El-Hak NG, Atif E. Surgical Management of Gastric Gastrointestinal Stromal Tumor: A Single Center Experience. *Saudi J Gastroenterol* 2011;17:189-93.
10. Anantha Madhavan, Alexander W. Phillips, Claire L. Donohoe, et al. Surgical Management of Gastric Gastrointestinal Stromal Tumours: Comparison of Outcomes for Local and Radical Resection. *Gastroenterol Res Pract* 2018;2018:7.
11. Seong-Ho Kong, Han-Kwang Yang, Surgical Treatment of Gastric Gastrointestinal Stromal Tumor. *J Gastric Cancer* 2013;13:3-18.
12. DeMatteo RP, Lewis JJ, Leung D, Mudan SS, Woodruff JM, Brennan MF. Two hundred gastrointestinal stromal tumors: recurrence patterns and prognostic factors for survival. *Ann Surg* 2000;231:51-8.