

Autoimmune Encephalitis in Brief

Man Amanat^{1,2}, Mona Salehi^{1,2}, Nima Rezaei^{3,4,5}

¹ NeuroImmunology Research Association (NIRA), Universal Scientific Education and Research Network (USERN), Tehran, Iran

² Students' Scientific Research Center, Tehran University of Medical Sciences, Tehran, Iran

³ Research Center for Immunodeficiencies, Children's Medical Center, Tehran University of Medical Sciences, Tehran, Iran

⁴ Department of Immunology and Biology, School of Medicine, Tehran University of Medical Sciences, Tehran, Iran

⁵ Network of Immunity in Infection, Malignancy, and Autoimmunity (NIIMA), Universal Scientific Education and Research Network (USERN), Tehran, Iran

Introduction

Limbic encephalitis, a relatively newly described condition, usually courses with an insidious onset of episodic memory loss, confusion, and agitation (1). The role of immune dysregulation in its pathophysiology has been extensively investigated. A recent study reported the prevalence and incidence rates of Autoimmune Encephalitis (AE) as 13.7/100,000 and 0.8/100,000 person-years which was not significantly different compared to infectious encephalitis (2). Herein, we summarize different aspects of AE.

Autoantibodies

Autoantibodies associated with AE are classified into two groups, based on their neuronal antigens (3). Over 15 antibodies have been recognized in adults, while only four have been identified in children (4). The target of group 1 autoantibodies is intra-cellular or onco-neuronal proteins of which Ri, Hu, Yo, and Ma are examples. These intracellular molecules are associated with paraneoplastic encephalitis and other underlying malignancies; such as lung cancer, skin cancer or testicular tumors (5). They have a poor outcome mainly as the result of irreversible neuronal damage. Antibodies targeting onco-neuronal antigens are not intrinsically pathogenic, but this may result in an autoimmune response to tumor antigens, which include proteins shared by the nervous system. The exception of this group is an anti-GAD antibody which seems to play a role in both acute seizures and chronic epilepsy (6). The second group consists of antibodies targeting neuronal surface antigens referred to as "neuronal surface antibodies" (NSAbs). Their neurological manifestation is known as "neuronal surface antibody syndromes" (NSAS) (7). These antigens are involved in synaptic signaling and plasticity.

Antigens in this group include those listed in box 1.

BOX 1:

N-methyl-D-aspartate receptor (NMDAR),
 α-methyl-4-isoxazolepropionic acid receptor (AMPA),
 gamma-aminobutyric acid (GABA) A and B,
 leucine-rich glutamate-inactivated 1 (LGI1),
 contactin-associated protein-like 2 (CASPR2),
 dipeptidyl-peptidase-like protein 6 receptor (DPPX),
 metabotropic glutamate receptor 5 (mGluR5),
 glycine receptor (GlyR),
 aquaporin 4 (AQP4),
 myelin oligodendrocyte glycoprotein (MOG).

Clinical manifestations

Prodromal viral symptoms, such as fever, rhinorrhea, and sore throat may be seen up to three weeks before the onset of AE manifestations (8). Most AEs, however, do not have a fever as part of their manifestations.

The onset may be insidious. Movement disorders, seizures, altered level of consciousness, lethargy, personality change, memory deficits, speech dysfunction and psychiatric symptoms such as psychosis in different combinations are common in AE (9). Recently, some specific characteristics have been described for some AEs; for instance, faciobrachial dystonic seizures and episodes of piloerection are now considered as pathognomonic features of anti-LGI1 AE (10,11).

Diagnosis

Diagnosis is reliant on antibody testing on serum or CSF samples. Some of the autoantibodies also act as prognostic biomarkers (12). In some types of AE such as anti-GAD, anti-NMDAR, anti-LGI1, and anti-CASPR2 encephalitis, the sensitivity of CSF is better than sera; while in encephalopathies associated with MOG and AQP4 serum samples are better than CSF

Corresponding Author: N. Rezaei

Department of Immunology and Biology, School of Medicine, Tehran University of Medical Sciences, Tehran, Iran
 Tel: +98 21 66929234, Fax: +98 21 66929235, E-mail address: rezaei_nima@tums.ac.ir

(13,14). Autoantibodies screening can be, however, problematic as it is not often accessible or available. When available results may take time to be returned. Therefore, focusing on clinical presentation and findings of complementary tests such as CSF, MRI and EEG should be the first step in the diagnosis.

Abnormal cerebrospinal fluid (CSF) is often present with predominant lymphocytic pleocytosis although this can also be seen in CNS infections. CSF findings cannot fully differentiate between AE and infectious encephalitis, but it can provide some differentiating markers. High CSF pleocytosis, protein concentrate, and decreased glucose are consistent with bacterial infections; while low pleocytosis with normal protein and glucose are more indicative of AE. Viral infections can have the same CSF findings as AE. Elevated neopterin and oligoclonal bands (OCBs) in CSF were also detected in both AE and infectious encephalitis (15).

The normal or non-specific finding are often seen in the magnetic resonance imaging (MRI); for instance, MRI is normal in approximately 60% of people with NMDA encephalitis (16). Conversely, specific patterns are often seen in infectious encephalitis.

Electroencephalography (EEG) is abnormal in most AE cases but could be normal in cases mainly involving the brainstem or cerebellum. To date, no clear diagnostic patterns have emerged from CSF, MRI and EEG findings to help distinguish all types of AE from infectious encephalitis. Some characteristic features have, however, for some types of AE which may help diagnosis. Extreme delta brush in EEG of patients with anti-NMDAR encephalopathy and multifocal MRI fluid-attenuated inversion recovery (FLAIR) abnormalities in anti-GABA_AR encephalitis are some of these features (17) (Table1).

A clinical approach for the diagnosis of AE was suggested in 2016, and these three criteria should be fulfilled for the diagnosis: 1) rapid progression or acute or subacute onset of psychiatric symptoms; 2) presence of recent focal CNS finding and/or unprovoked seizures and/or CSF pleocytosis and/or MRI patterns associated with encephalitis; and 3) exclusion of other causes (18). The differential diagnosis of AE is vast and includes

systemic autoimmune disorders, infections, alcohol or drug abuse (Wernicke encephalitis) and a neuroleptic malignant syndrome which must all be excluded. Seizures can be the sole manifestation of AE, and these cases can be a diagnostic challenge as the first criteria will not be fulfilled unless unprovoked seizures are moved into the first criteria.

Treatment

For patients with a definite diagnosis of AE, the first line of therapy consists of corticosteroids with the combination of intravenous immunoglobulin (IVIg) and/or plasmapheresis. Using IV solumedrol (1 gram daily for 3-5 days then a taper for several weeks) and IVIg (0.4 gram/kg/day for 5 days) is one of the suggested treatments (19). Improvement may occur 2 weeks or more, after starting the first line. If no betterment was achieved during this time or in subjects with severe symptoms such as comatose, the second line of treatment should be added to the previous therapy. Cyclophosphamide and rituximab are the mentioned second-line medications in studies. 750 mg/m² IV cyclophosphamide monthly until the improvement will be achieved or 375 mg/m² rituximab weekly for 4 weeks, is frequently used as the second line of treatment (19).

If an individual is suspected for AE, but the process of diagnosis is not complete, IVIg and plasmapheresis can be used as empirical treatment. Of note, corticosteroids may worsen infectious encephalitis or CNS lymphoma but no data is existed to show that IVIg or plasmapheresis may affect these aforementioned conditions (20) and they can be used safely in suspected AE patients. In cases with paraneoplastic encephalitis, early use of immunotherapy can be useful, but the treatment of underlying malignancies should be noted too (Figure1).

Acknowledgments

The authors are grateful to Pro Ley Sander for a helpful review.

Table 1. Clinical and para-clinical features associated with the most common neuronal surface antibody syndromes

Antigen	Median age (years)	Sex	Neurological manifestations	Occurs in children	Abnormal CSF (%)	EEG findings	MRI findings
LGII	60	M>F	FBDS, Tonic seizures, Myoclonus, Dementia, Limbic encephalitis, Sleep disorders, piloerection, episodes of dizzy spell	No	40%	Ictal 2-4Hz epileptiform event , PLEDs and temporal epileptic discharge	Hippocampal high T2 signal with unilateral or bilateral medial temporal lesions FLAIR hyper-intensities in temporal regions Basal ganglia hyper-intensity in about 90% of patients with FBDS
CASPR2	60	M>F	Neuromyotonia, Fasciculations Morvan's syndrome, Limbic encephalitis, Sleep disorders	No	25%	Similar to LGII in EEG findings	Hippocampal high T2 signal with unilateral or bilateral medial temporal lesions FLAIR hyper-intensities in temporal regions
GABAaR	40	M=F	Cognitive dysfunction, Depression, Psychosis, Ataxia	Yes	66%	GPD	75% of patients have multifocal extensive FLAIR and T2 hyper-intense MRI abnormalities with numerous involved cortical and subcortical brain regions
GABA_bR	60	M>F	Seizure, Limbic encephalitis	No	80-90%	Diffuse slowing and bilateral periodic lateralized epileptiform discharges	Increased FLAIR signal in the medial temporal lobe of both hemispheres
AMPAR	60	M<F	Limbic encephalitis, Psychosis	No	90%	Ictal 2-4Hz epileptiform event , PLEDs and temporal epileptic discharge	No specific pattern
NMDAR	20	M<F	Behavioral changes, Psychosis, Seizure, Aphasia, Movement disorders, Central hypoventilation, Dysautonomia	Yes	90%	Extreme delta brush in few patients and PLEDs	Approximately 40% of patients with transient cortical or subcortical brain, cerebellar or brainstem abnormalities. Advanced MRI techniques indicated reduced functional connectivity of hippocampi and white matter changes
mGLUR5	30	M=F	Behavioral changes, Memory deficit, Confusion	Yes	100%	Pronounced IRDAs	Non-specific white matter lesions, atrophy and temporal lobe inflammation
DPPX	60	M>F	Tremor, Sleep disorder, Depression, Psychosis, Dysautonomia, Brainstem or spinal cord disorders	No	30%	No specific pattern	Non-specific white matter changes
GlyR	50	M=F	Encephalomyelitis, Stiff person syndrome, Myoclonus, Hyperekplexia	No	60%	No data	No data

NMDAR: N-methyl-D-aspartate receptor; AMPAR: a-methyl-4-isoxazolepropionic acid receptor; GABA a and bR: gamma-amino butyric acid; LGII: leucine-rich glutamate inactivated 1; CASPR2: contactin-associated protein like 2; DPPXR: dipeptidyl-peptidase-like protein 6 receptor; mGLUR5: metabotropic glutamate receptor 5; GlyR: glycine receptor; M: male; F: female; FBDS: faciobrachial dystonic seizures; MRI: magnetic resonance imaging; PLEDs: periodic lateralized epileptiform discharges; GPD: generalized periodic discharges; IRDA: intermittent rhythmic delta activity

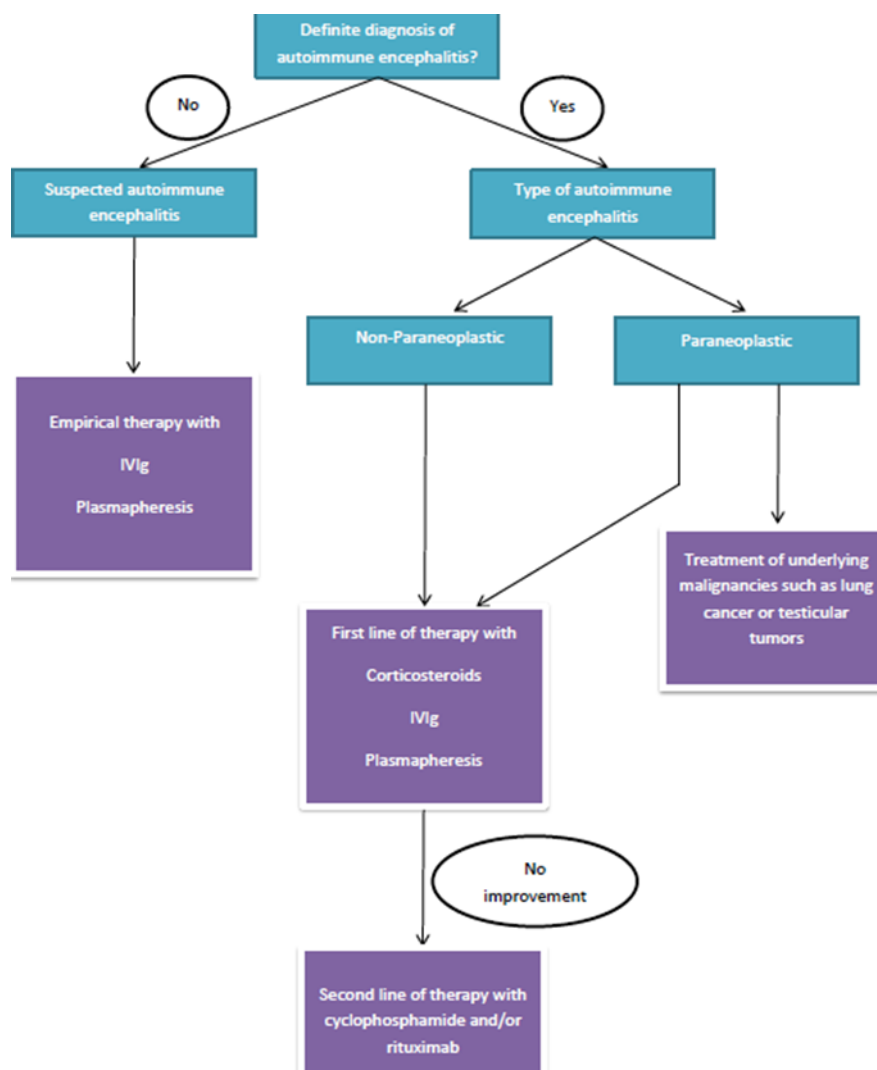


Figure 1. Treatment of autoimmune encephalitis

References

- Vincent A, Buckley C, Schott JM, Baker I, Dewar BK, Detert N, et al. Potassium channel antibody-associated encephalopathy: a potentially immunotherapy-responsive form of limbic encephalitis. *Brain* 2004;127:701-12.
- Dubey D, Pittock SJ, Kelly CR, McKeon A, Lopez-Chiriboga AS, Lennon VA, et al. Autoimmune Encephalitis Epidemiology and a comparison to Infectious Encephalitis. *Ann Neurol* 2018;83:166-77.
- Kelley BP, Patel SC, Marin HL, Corrigan JJ, Mitsias PD, Griffith B, et al. Autoimmune Encephalitis: Pathophysiology and Imaging Review of an Overlooked Diagnosis. *AJNR Am J Neuroradiol* 2017;38:1070-8.
- Armangue T. Autoimmune encephalitis in children. *Gesundheitswesen* 2015;77:880.
- Leyboldt F, Wandinger KP. Paraneoplastic neurological syndromes. *Clin Exp Immunol* 2014;175:336-48.
- Daif A, Lukas RV, Issa NP, Javed A, VanHaerents S, Reder AT, et al. Antiglutamic acid decarboxylase 65 (GAD65) antibody-associated epilepsy. *Epilepsy Behav* 2018;80:331-6.
- Ramanathan S, Mohammad SS, Brilot F, Dale RC. Autoimmune encephalitis: recent updates and emerging challenges. *J Clin Neurosci* 2014;21:722-30.
- Dubey D, Alqallaf A, Hays R, Freeman M, Chen K, Ding K, et al. Neurological autoantibody prevalence in epilepsy of unknown etiology. *JAMA Neurol* 2017;74:397-402.

Autoimmune encephalitis

9. Irani SR, Miller TD, Vincent A. Autoimmune encephalitis. In Oxford Textbook of Cognitive Neurology and Dementia. UK: Oxford University Press, 2016.
10. Gadoth A, Pittock SJ, Dubey D, McKeon A, Britton JW, Schmeling JE, et al. Expanded phenotypes and outcomes among 256 LGI1/CASPR2-IgG positive patients. *Ann Neurol* 2017;82:79-92.
11. Dubey D, Toledano M, McKeon A. Clinical presentation of autoimmune and viral encephalitides. *Curr Opin Crit Care* 2018;224:80-90.
12. Lancaster E and Dalmau J. Neuronal autoantigens—pathogenesis, associated disorders and antibody testing. *Nat Rev Neurol* 2012;8:380-90.
13. Armangue T, Santamaria J, Dalmau J. When a serum test overrides the clinical assessment. *Neurology* 2015;84:1379-81.
14. Höftberger R, Sepulveda M, Armangue T, Blanco Y, Rostásy K, Calvo AC, et al. Antibodies to MOG and AQP4 in adults with neuromyelitis optica and suspected limited forms of the disease. *Mult Scler* 2015;21:866-74.
15. Kothur K, Wienholt L, Mohammad SS, Tantsis EM, Pillai S, Britton PN, et al. Utility of CSF cytokine/chemokines as markers of active intrathecal inflammation: comparison of demyelinating, anti-NMDAR and enteroviral encephalitis. *PLoS One* 2016;11:e0161656.
16. Finke C, Kopp UA, Scheel M, Pech LM, Soemmer C, Schlichting J, et al. Functional and structural brain changes in anti-N-methyl-D-aspartate receptor encephalitis. *Ann Neurol* 2013;74:284-96.
17. Spatola M, Dalmau J. Seizures and risk of epilepsy in autoimmune and other inflammatory encephalitis. *Curr Opin Neurol* 2017;30:345-53.
18. Graus F, Titulaer MJ, Balu R, Benseler S, Bien CG, Cellucci T, et al. A clinical approach to diagnosis of autoimmune encephalitis. *Lancet Neurol* 2016;15:391-404.
19. Lancaster E. The diagnosis and treatment of autoimmune encephalitis. *J Clin Neurol* 2016;12:1-3.
20. Haley M, Retter AS, Fowler D, Gea-Banacloche J, O'Grady NP. The role for intravenous immunoglobulin in the treatment of West Nile virus encephalitis. *Clin Infect Dis* 2003;37:e88-90.