

Multiple Paratesticular Fibrous Pseudotumors in an Adult Patient: Case Report

Mehdi Kardoust Parizi¹, Seyed Ali Momeni², Ghazal Ameli³

¹ Department of Urology, Shariati Hospital, Tehran University of Medical Sciences, Tehran, Iran

² Department of Urology, Uro-Oncology Research Center, Tehran University of Medical Sciences, Tehran, Iran

³ Department of Urology, Clinic Korneuburg, Korneuburg, Austria

Received: 11 Jul. 2018; Accepted: 10 Nov. 2018

Abstract- Paratesticular fibrous pseudotumors (PFP) are relatively rare benign spindle cell tumors. These tumors usually are originated from testicularis tunics and grow into the epididymis and spermatic cord. PFP is a consequent of a reactive proliferation of inflammatory tissue. We report a case of PFP with simultaneous multiple tunica albuginea and tunica vaginalis lesions. A 33-year-old man presented with painless right scrotal lump, normal serum tumor markers, and one centimeter paratesticular mass in ultra-sonography that underwent testis-sparing surgery due to a benign microscopic appearance in frozen section evaluation. Testis sparing surgery can be considered as the preferred management because of the lack of obvious evidence of potential malignancy in this tumor.

© 2019 Tehran University of Medical Sciences. All rights reserved.

Acta Med Iran 2019;57(3):194-196.

Keywords: Paratesticular fibrous pseudotumors; Benign

Introduction

Fibrous paratesticular pseudotumor (PFP) is considered as a rare tumor of paratesticular region with benign behavior; it accounts for approximately 6% of all paratesticular lesions (1,2). This tumor usually originates from the tunica albuginea or tunica vaginalis. PFPs present typically as painless multinodular scrotal masses and can clinically mimic a malignancy. Therefore it can be challenging to establish the diagnosis in the preoperative period. In this case report, we present a PFP case with simultaneous multiple tunica albuginea and tunica vaginalis lesions.

Case Report

A 33-year-old man presented due to a pain-free lump on the right testicle since 6-months ahead of the visit. There was no previous surgical, traumatic or any other significant history. Physical examination showed a one centimeter non-tender extra testicular mass in the right hemiscrotum; the mass was soft and immobile. The left testis was normal, and there were no palpable abdominal and inguinal lymph nodes. Scrotal ultrasound examination showed a hypoechoic circumscribed paratesticular lesion about one centimeter over the superior surface of the right testis mass. All serum tumor

markers including human chorionic gonadotropin of 3 mIU/ml, α -fetoprotein of 4 ng/ml and lactate dehydrogenase of 280 U/L were in the normal range.

On surgical exploration, three lesions were seen in the right hemiscrotum. One large lesion in the tunica vaginalis and two smaller lesions over the tunica albuginea (Figure 1).

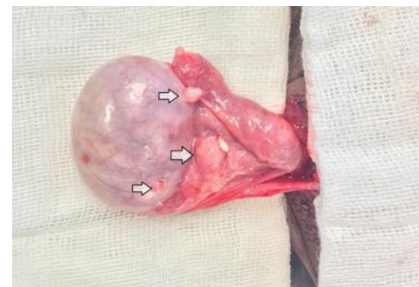


Figure 1. Right testis exploration (white arrows show three lesions of tunica albuginea and tunica vaginalis)

Intraoperative frozen section evaluation revealed benign tissue, so the patient underwent testis-sparing surgery. The definitive pathological diagnosis was reported as dense fibrous tissue, fibroblasts, inflammatory cells and dystrophic calcification compatible with fibrous pseudotumor (Figure 2).

No recurrences have been noted after 12 months of follow-up.

Corresponding Author: S.A. Momeni

Department of Urology, Uro-Oncology Research Center, Tehran University of Medical Sciences, Tehran, Iran
Tel: +98 912 2082402, Fax: +98 21 66903063, E-mail address: samomeni@sina.tums.ac.ir

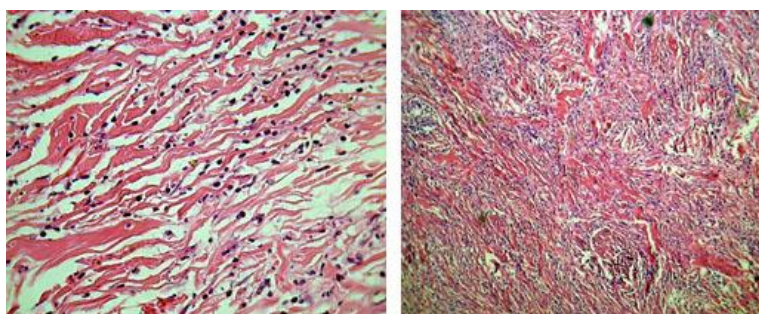


Figure 2. The proliferation of typical fibroblasts distributed in multidirectional bundles of dissociated collagen fibers (H and E×10 and 40)

Discussion

Fibrous Pseudotumor is an uncommon and benign spindle cell tumor that has been described in nearly every organ, including the lung, gastrointestinal tract, retroperitoneum, central nervous system, extremities, and the genitourinary tract (3). It accounts for nearly 6% of all paratesticular lesions and represents the second most common paratesticular lesion after adenomatoid tumor (1,2,4). Fibromatous lesions of testicular tunics were recognized first by Sir Astely Cooper in 1830 (5).

The relative incidence of PFP in relation to germ cell tumors of testis has been reported to be 1:200 (6). These lesions are thought to be reactive in nature and are composed of dense fibrous tissue with bland fibroblast and myofibroblast, and mixed inflammatory cells. This non-neoplastic masses originate mostly in the tunica vaginalis (76%) and rarely in the epididymis (10%), or tunica albuginea (14%) (7). So, localization of PFP in tunica albuginea is unusual.

In this case report, we demonstrated a PFP with multiple tunica albuginea and tunica vaginalis lesions.

The etiology of PFP is poorly understood and highly controversial, but it is most accepted as a reparative process in response to trauma, chronic irritation, or infection (1,3).

Paratesticular fibrous pseudotumors usually present as a unilateral painless mass and are more common on the left side, ranging in size from 0.5 to 8 cm, though tumors as large as 25 cm have also been reported (3,8). There are also reported cases with PFP on the right side (6). In our case, all three lesions were also localized on the right scrotum. Therefore, evidence pointing to the predominate of one particular side is probably weak.

The peak incidence of PFP is in the third decade but may occur at any age, in a review, Miyamoto *et al.*, reported a mean age of presentation of 42 years (9).

Many different terms have been used to refer PFPs: nodular and diffuse fibrous proliferation, chronic proliferative periorchitis, inflammatory pseudotumor, and nodular periorchitis. It is classified as a tumor of intermediate biologic potential by the world health organization due to the tendency of local recurrence and low risk of distant metastasis (10). Most patients report a history of hydrocele, trauma or infection. Hydrocele has been found in nearly 50% of fibrous pseudotumors (7). Clinically, our patient had no previous surgical, traumatic or any other significant history and reported the typical clinical findings with a painless mass.

The fact that PFP might be a manifestation of an IgG4 related sclerosing disease in the paratesticular region was first reported by Bösmüller *et al.*, (11).

In the evaluation of scrotal masses, ultrasonography is the most accurate imaging tool, but the appearance of PFPs are frequently nonspecific. They may present as either hyperechoic or hypoechoic lesions depending on the degree of calcification, hyalinized collagen, granulation tissue, and the lesion might be separated from the testes (8,12). Although MRI of PFP has been reported in only a few cases, some studies have shown a specific appearance with an extratesticular multiple nodular lesion that exhibits intermediate-to-low signal intensity on T1- and T2-weighted images, with little or no gadolinium enhancement (13,14).

This lesion presents commonly as multinodular, well delimited and mobile structures (4,7). Microscopically, the nodes are composed of dense fibrous tissue that consists of hyalinized collagen and spindle fibroblasts in different proportions (7). Mitotic figures are rare; other findings may include calcification, myxoid change, granulation, and infiltration of lymphocytes, plasma cells, and histiocytes (4). Diffuse CD34 immunoreactivity has been reported as a prominent finding in PFP. Immunohistochemical positive markers include CD99,

Paratesticular fibrous pseudotumors

vimentin, and smooth muscle-specific actin. In contrast, PFP generally shows negative expression of S100, cytokeratin, SMA, CD117, CD31, and desmin. The differential diagnosis of PFP includes other types of spindle cell tumors such as angiomyolipoma, leiomyoma, inflammatory myofibroblastic tumor, and gastrointestinal stromal tumor (15).

As in our case scrotal exploration, frozen biopsy and local excision is the treatment of choice, but most patients undergo radical orchidectomy because their mass mimics a malignancy (7). The efficacy of frozen section assessment for testicular and paratesticular lesions is suspected. However some studies reported that frozen section assessment could help in preventing unnecessary radical orchiectomy (83.7%) for a benign diagnosis (16). In our case, the frozen section at the time of surgery helped us to perform testis-sparing surgery. Radical orchiectomy should be performed if the malignancy is doubtful or if the testicular tumor cannot be excluded with certainty (1).

PFPs are the most rarely seen benign tumors, and two third involve the testicular tunica with rare involvement of other scrotal structures. These tumors should be considered as a differential diagnosis of paratesticular masses and may be managed safely by testicular sparing surgery.

References

1. Harel M, Makari JH. Paratesticular inflammatory myofibroblastic tumor in a pediatric patient. *Case Rep Urol* 2014;2014:303678.
2. Jones MA, Young RH, Scully RE. Benign fibromatous tumors of the testis and paratesticular region: a report of 9 cases with a proposed classification of fibromatous tumors and tumor-like lesions. *Am J Surg Pathol* 1997;21:296-305.
3. Singh M, Gupta D, Amit S. Paratesticular Fibrous Pseudotumor. *J Case Rep* 2016;6:47-50.
4. Ugras S, Yesil C. Fibrous pseudotumors of tunica albuginea, tunica vaginalis and epididymis: report of two cases. *Cancer Epidemiol* 2009;33:69-71.
5. Ulbright TM, Amin MB, Young RH. Atlas of Tumor Pathology: Tumors of the Testis, Adnexa, Spermatic Cord, and Scrotum 1999. M. D. Juan Rosai & Leslie H. Sobin (eds). Available from the American Registry of Pathology, Armed Forces Institute of Pathology, Washington, D.C. 20306-6000. *Int J Androl* 2000;23:254.
6. Dieckmann KP, Struss WJ, Frey U, Nahler-Wildenhain M. Paratesticular fibrous pseudotumor in young males presenting with histological features of IgG4-related disease: two case reports. *J Med Case Rep* 2013;7:225.
7. Seethala RR, Tirkes AT, Weinstein S, Tomaszewski JE, Malkowicz SB, Genega EM. Diffuse fibrous pseudotumor of the testicular tunics associated with an inflamed hydrocele. *Arch Pathol Lab Med* 2003;127:742-4.
8. Tobias-machado M, Corrêa Lopes Neto A, Heloisa Simardi L, Borrelli M, Wroclawski ER. Fibrous pseudotumor of tunica vaginalis and epididymis. *Urology* 2000;56:670-2.
9. Miyamoto H, Montgomery EA, Epstein JI. Paratesticular fibrous pseudotumor: a morphologic and immunohistochemical study of 13 cases. *Am J Surg Pathol* 2010;34:569-74.
10. Gleason BC, Hornick JL. Inflammatory myofibroblastic tumours: where are we now? *J Clin Pathol* 2008;61:428-37.
11. Bösmüller H, von Weyhern CH, Adam P, Alibegovic V, Mikuz G, Fend F. Paratesticular fibrous pseudotumor—an IgG4-related disorder? *Virchows Arch* 2011;458:109-13.
12. Hamm B. Differential diagnosis of scrotal masses by ultrasound. *Eur Radiol* 1997;7:668-79.
13. Al-Otaibi L, Whitman GJ, Chew FS. Fibrous pseudotumor of the epididymis. *Am J Roentgenol* 1997;168:1586.
14. Cassidy FH, Ishioka KM, McMahon CJ, Chu P, Sakamoto K, Lee KS, et al. MR imaging of scrotal tumors and pseudotumors. *Radiographics* 2010;30:665-83.
15. Gold JS, Antonescu CR, Hajdu C, Ferrone CR, Hussain M, Lewis JJ, et al. Clinicopathologic correlates of solitary fibrous tumors. *Cancer* 2002;94:1057-68.
16. Leroy X, Rigot JM, Aubert S, Ballereau C, Gosselin B. Value of frozen section examination for the management of nonpalpable incidental testicular tumors. *Eur Urol* 2003;44:458-60.