

INTRA PERICARDIAL RUPTURE OF LIVER AMEBIC ABSCESS

S. Sarkissian

Cancer Institute, Pahlavi Hospital, Tehran

M.R.H. Male-aged 30. Labourer.

Patient was admitted to the Hospital on account of intermittent fevere, pain in right hypochondrium, which started six months ago, during that period patient had lost considerable weight and the appetite was poor. He looked pale and anaemic, there was no shortness of breath and had no history of other illness.

On Examnation Lung clear, B.P. 120/85, on ascultation heart sounds normal. The liver was enlarged, soft, tender, otherwise the adbomen felt normal. Blood Picture. E.S.R. 114 mm. 1st. hour. R.B.C. 3,500,000. W.B.C. 12000 with 74% polymorphs. Chest x-ray Fig 1 appeared to be normal.

On screenirgh the chest, lung were clear and diaphragm had normal movement. On the 5th. day after admission patient suddenly developed a severe precordial pain with extreme shortness of breath; On the next day shortness of breath and pain increased, the patient became cyanosed, very distressed, another chest x-ray (Fig. 2) was taken, when compared with the previous one it showed slight enlargement of heart shadow, otherwise no other abnormality. Pulse rate was about 180 permin. Very week and B.P. impercitable, and patient died on the same day.

P.M. Showed an enormous abscess in the left lobe of the liver which had perforated the diaphragm into the perciardium and had caused suppurative pericardities and cardiac tamponade. Fig 3-4-5 and 6.

Discussion

Extention of subphrenic infection into pleural cavity is a frequent complication, according to Harley's survey of subphrenic abscesses, puts this complication at about 9.9% in acute cases and 37.5% in the chronic cases.

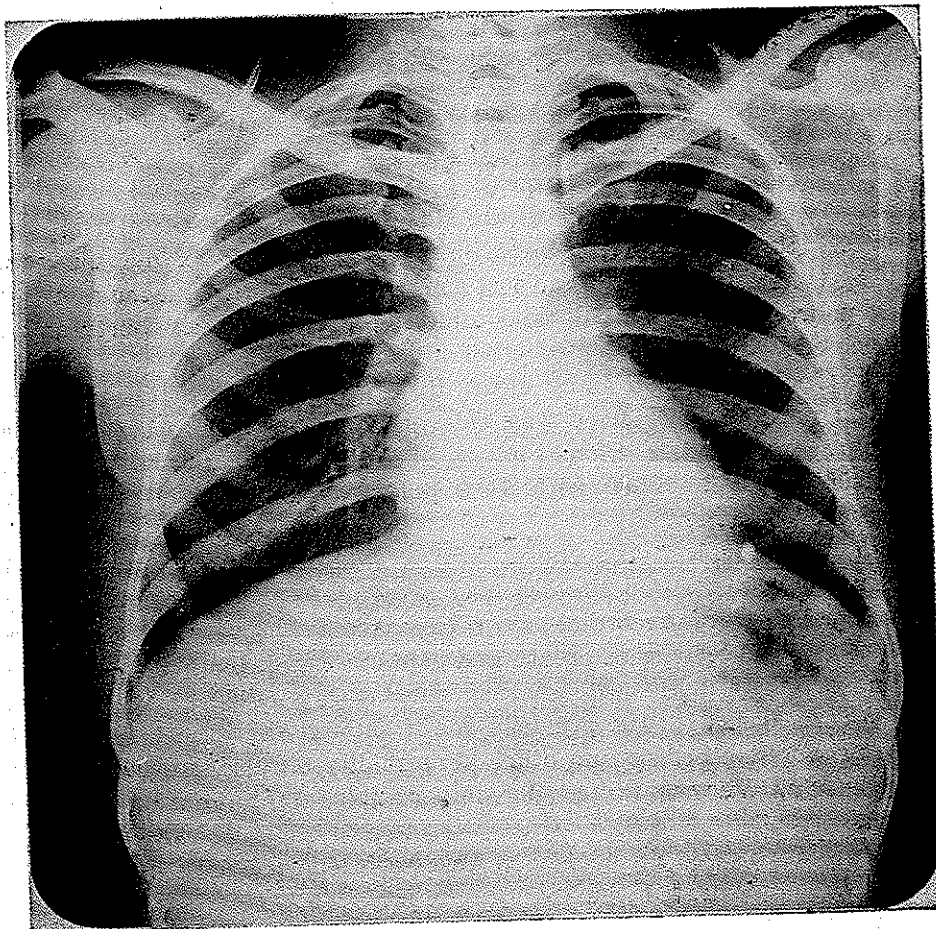


Fig. 1. Chest X ray shows no abnormality

Pleural reaction together with formation of exudates in the pleural cavity is more frequent complication in subphrenic infection.

Although Harley mentions left sided pleural cavity complication he never mentions pericardial involvement, obviously the diaphragm where it is fused with the pericardium is very much thicker and will stand pressure necrosis more so than the rest.

The urgency of diagnosis of such a complication needs no emphasis, and it requires bearing in mind that such a complication may occur.

Looking back at the case there were two points which should have been a guide to diagnosis, one-extreme shortness of breath with no apparent reason (heart, lung normal) and secondly-comparing the two x-rays which had been taken within two days, showed enlargement of heart shadow; this enlargement although very slight is important as it had developed so quickly and was accompanied, by increase in shortness of breath and precordial pain.

Summary:

A case of liver abscess ruptured into pericardium is described and its diagnosis discussed

Résumé

Un Cas d'abcès du foie perforé dans le péricarde est décrit et son diagnostic est discuté.

References

- Harley H.R.S. Thorax 1949
Harley 1955 Ann Roycoll surgen

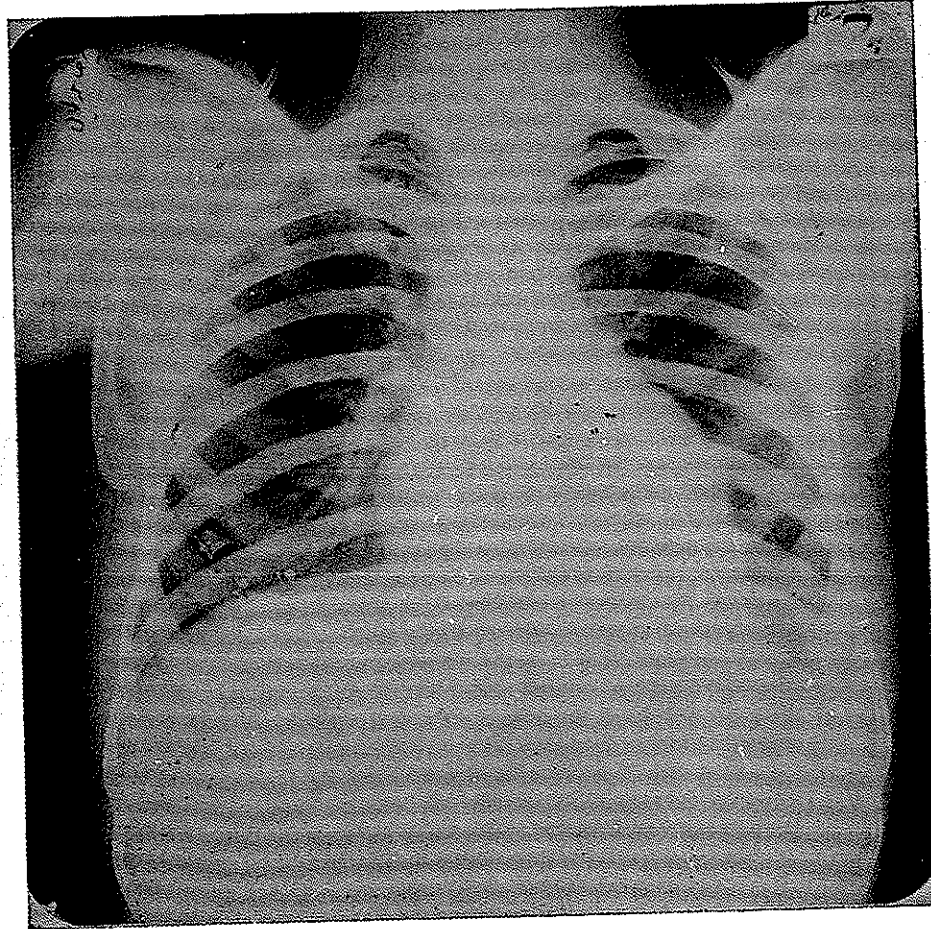


Fig. 2. Chest X ray two days later shows enlargement of heart shadow.

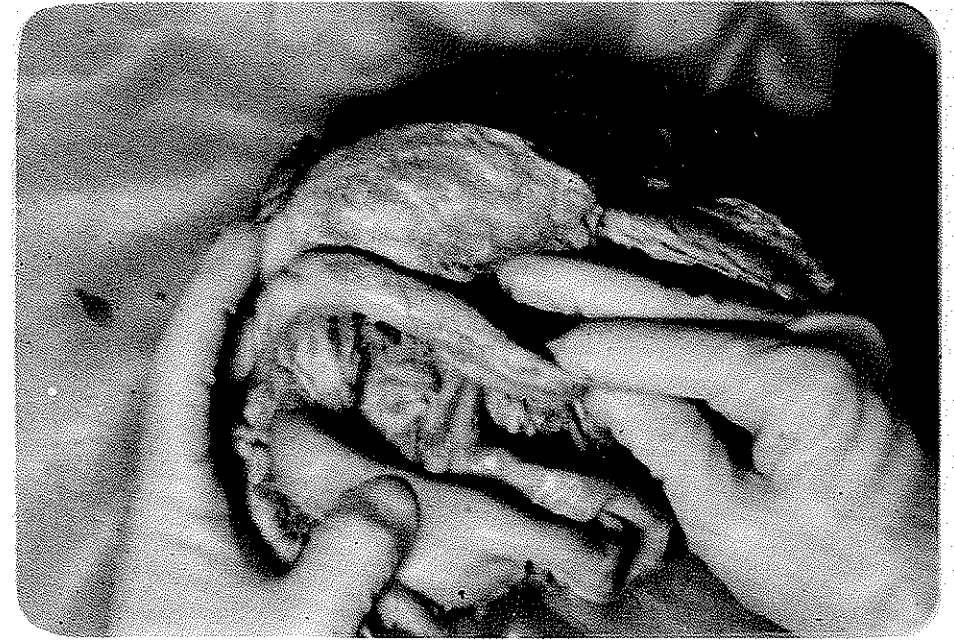


Fig 3 - A match stick is passed through the perforation of diaphragm

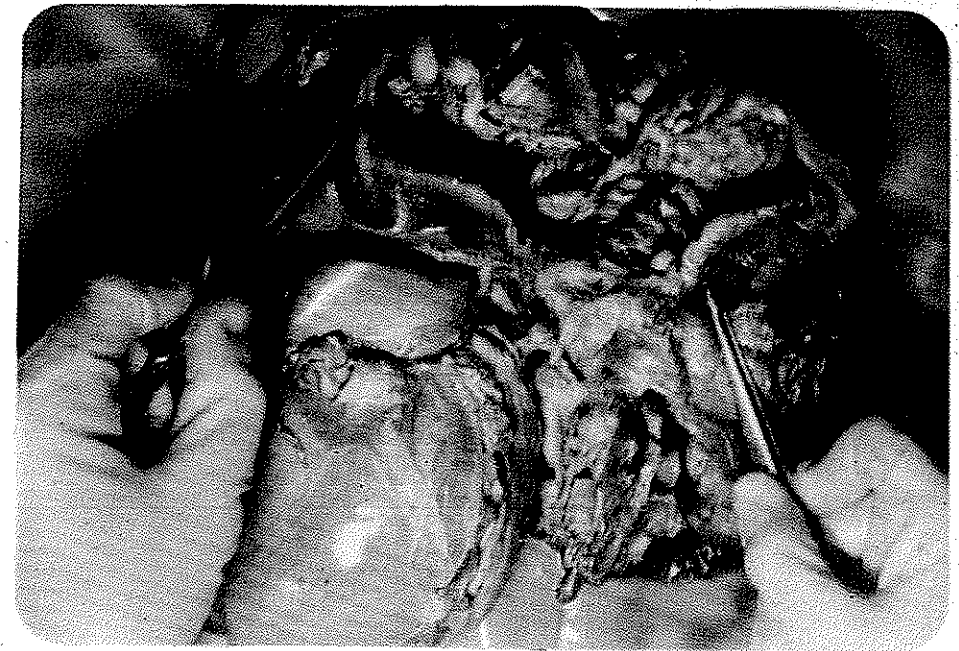


Fig 4 - Abscess cavity

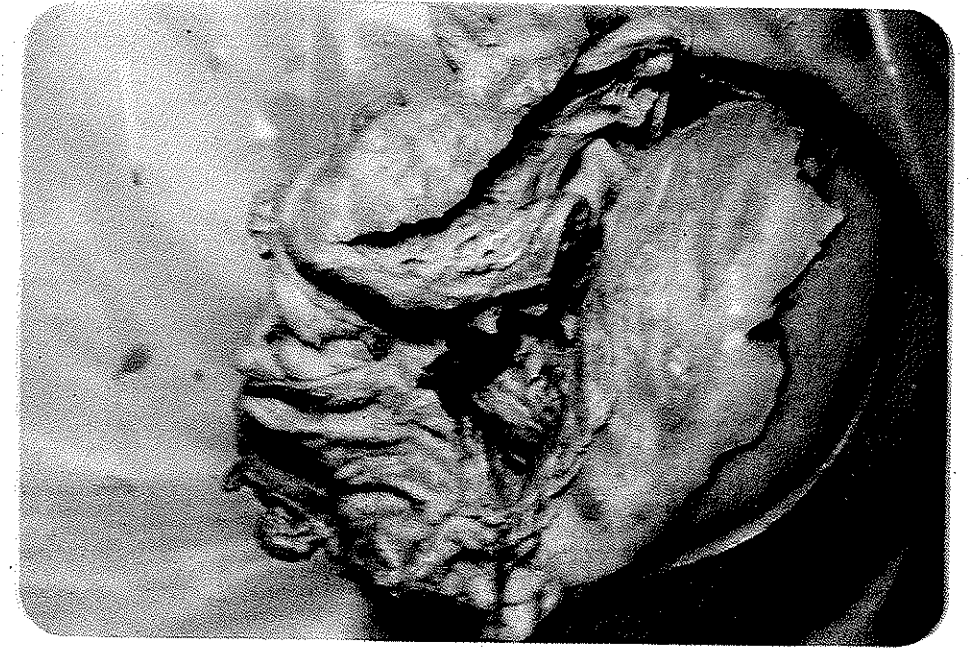

Fig 5 - Pericardium shows infection

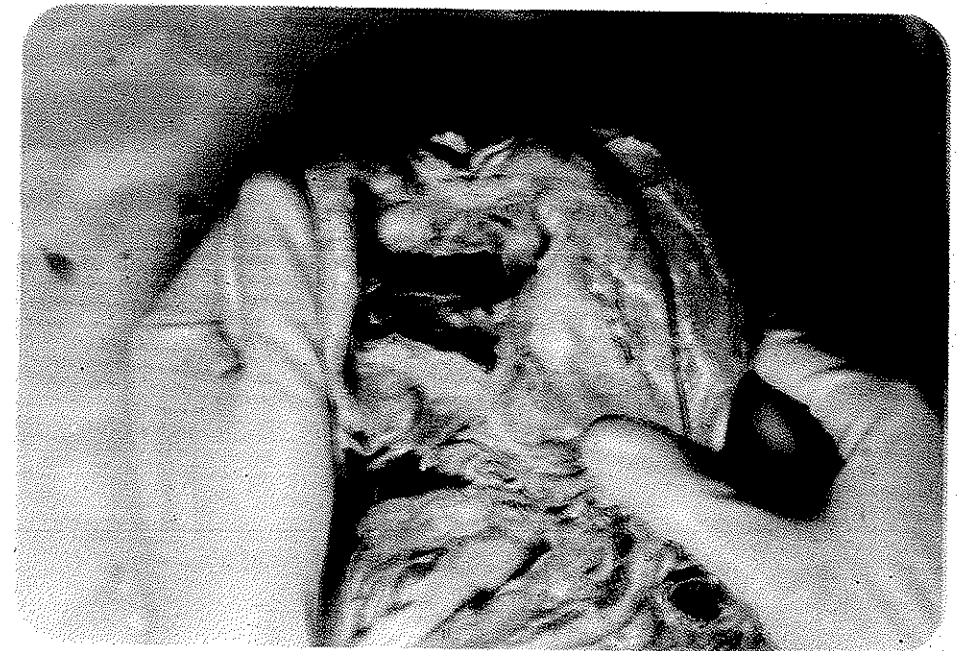


Fig 6 - Perforation as viewed from above