

Appendicostomy Antegrade Colonic Irrigation by Electromechanical Pump: A Novel Method for Managing Fecal Incontinence, Randomized Clinical Trial

Seyed Hamzeh Mousavie^{1,2}, Rezvan Mirzaei³, Bahar Mahjoubi³, Amir Nahavandi³

¹ Department of Surgery, Colorectal Research Center (CRRC), Iran University of Medical Sciences, Tehran, Iran

² Rasoul-e-Akram Hospital, Iran University of Medical Sciences, Tehran, Iran

³ Colorectal Research Center (CRRC), Rasoul-e-Akram Hospital, Iran University of Medical Sciences, Tehran, Iran

Received: 09 Sep. 2018; Accepted: 14 Nov. 2018

Abstract- Antegrade colonic irrigation enema (ACIE) is established as an old treatment for child fecal incontinence and recently is approved as a treatment for different causes of adult fecal incontinence (cancer surgery, neurogenic bowel, spinal cord injury, sphincter trauma, etc.). Despite the benefits of emptying the large bowel and prevention of fecal incontinence or constipation, this method is time-consuming and requires thorough instruction and training. The purpose of this study was to innovate and assess novel technique to decrease time-consuming and improve performance of irrigation. We designed and electromechanical pump for colon irrigation and assessed by a randomized crossover clinical trial study, involving two-four weeks treatment phases. 30 patients have included that suffered fecal incontinence and had been managed with appendicostomy antegrade colon irrigation. The results showed that the pump decrease time and volume of irrigation compare with the traditional method. All patients had a reduction in toileting times. Traditional mean toileting time was 67 minutes, versus pump-toileting time that was 24.6 minutes ($P:0.00$). The volume of water was reduced in 13 patients. Mean of the volume was 1712 ml in the traditional method and 1128 ml in pump method ($P:0.279$). Mean Cleveland Clinic Florida Fecal Incontinence score (CCF_FIS) for the pump was 5.84 compare 6.24 for traditional method ($P:0.000$). Our study provides evidence for the first time that our novel method can facilitate and speed-up colon irrigation without any adverse effect on the outcome.

© 2019 Tehran University of Medical Sciences. All rights reserved.

Acta Med Iran 2019;57(4):216-223.

Keywords: Appendicostomy; Antegrade colon irrigation (ACIE); Fecal incontinence

Introduction

Fecal incontinence is a condition that is socially stigmatized and has attracted labels such as “the silent affliction” and “the unvoiced symptom”(1). Fecal incontinence or soiling that is fecal leakage without awareness is usually associated with dysfunction of the smooth muscle tissue of the internal anal sphincter or with impacted stool in the rectum (2,3), but multiple mechanisms may be involved in its pathophysiologies, such as altered stool consistency and delivery of contents to the rectum, abnormal rectal capacity or compliance, decreased anorectal sensation, and pelvic floor or anal sphincter dysfunction (4).

In a referral center, sphincter damage after anal surgery is the commonest cause of incontinence after obstetric trauma. Incontinence may be unavoidable for example, after complex anal fistula surgery, lateral

internal sphincterotomy, and ileal pouch reconstruction. It may also occur as an unexpected complication of a simple operation. Also, incontinence may occur when the sphincter is excited as part of surgical treatment for example in rectal cancer surgery (5,6).

Many patients with the neurological disease have fecal incontinence that may impair their quality of life as much as the primary disorder. spinal injuries, spinabifida, anal atresia (7,8).

The prevalence of fecal incontinence appears to be more common than previously appreciated (9). and fecal incontinence is the second commonest reason for requesting placement in a nursing home (10). A third of elderly people in retirement homes or hospital is incontinent for stool (5,6). In patients with spinal injuries, 61% had fecal incontinence. 90% of patients with spinabifida suffered from fecal incontinence (7,8).

In some patients, First line therapy is conservative

Corresponding Author: R. Mirzaie

Colorectal Research Center (CRRC), Rasoul-e-Akram Hospital, Iran University of Medical Sciences, Tehran, Iran
Tel: +98 912 0717966, Fax: +98 21 42910703., E-mail address: Mirzaei.r@iums.ac.ir

measures aimed at symptomatic control. Dietary regimens, fibers, constipating agents and enemas may be tried. Biofeedback is an option to strengthen the external anal sphincter, improve rectal sensitivity and coordinate pelvic floor muscles. Colonic irrigation has been successful to reduce symptoms and improve quality of life. Finally, Surgical interventions may be considered if conservative management fails (11).

Colonic irrigation can be carried out through retrograde irrigation, or through antegrade. Some Studies have shown that up to 92_97% of patients with abdominal colostomies may achieve continence with retrograde colostomy irrigation hereby improving their physical well-being and quality of life (12-15). But another study demonstrates that colonic emptying is more efficient with antegrade irrigation compared to retrograde irrigation (16). The newer approach with antegrade irrigation through an appendicostomy or cecal access in perineal stoma patients has been shown to improve the continence rate to 84.6% (14). Colonic irrigation can be used effectively to treat defecation disorders when other conservative treatments fail or in addition to unsuccessful or partially successful surgical treatment (17).

The first description of antegrade colonic irrigation was made over 100 years ago. The concept of antegrade continence enema (ACE) procedure was proposed and popularized by Malone *et al.*, the goal was to improve the quality of life in children with fecal incontinence (18,19).

The original Malone technique was a right lowers abdomen incision for dissecting appendix and a small cuff of cecum with its preserved blood supply (18). This technique was soon taken over by orthotropic appendicostomy with maintaining native blood supply to the appendix. It was advised to imbricate around the base of the appendix and also cecal fixation to the inside of the abdominal wall to make it continent (14,20,21). The recent trend is towards minimally invasive procedures. Various operative techniques used successfully were laparoscopic-assisted ACE, laparoscopic-assisted cecal button, laparoscopic-assisted percutaneous colostomy and percutaneous endoscopic cecostomy and colostomy (22-25).

Many studies showed that the ACE is feasible and effective in adult patients. Most patients were satisfied with the outcomes. All patients that were evaluated in these studies suffered from fecal incontinence. However, there were different causes of incontinence such as neurogenic bowel disease, spinal cord injury, spinabifida, rectal cancer operation and anal sphincter injury (26-30).

Although, some studies showed that irrigation through an appendicostomy has been safe and efficient in

patients suffering refractory constipation and overflow incontinence or severe constipation (29-32).

With proved treatment and increased survival of rectal tumors, there is a growing need for control of fecal incontinence due to low anterior resection or abdominoperineal resection. Perineal colostomy with appendicostomy for antegrade continence enema is a valid and acceptable alternative for a permanent abdominal colostomy in selected patients, that improved better functional and quality of life outcome (26,33-37).

Despite benefits and profits, antegrade irrigation through appendicostomy is time-consuming and requires thorough instruction and training. In literature, at least mean evacuation and irrigation time is described from 40 min to 70 min. several efforts were done for shortening of this duration and improve outcome (18,38-40).

We designed and electromechanical pump and assessed the effect of water infusion through appendicostomy by the pump in time-consuming and improving the performance of irrigation

Materials and Methods

The study was set in a specialized colorectal center that acts as a referral center. We designed and electromechanical pump that based on obtained information from the pumps used in CT-colonography, water jet irrigation for cleaning the colon during an emergency colonoscopy, and same pumps used for retrograde colon irrigation. (33,38,41-43) for this purpose, we assessed pressure and volume of water that was used in traditional colon irrigation. Finally, the pump was made that characteristics were: flow rate: 6 ml/s, outlet catheter size: 10 F, head: 195 cm.

Ethical approvals for this study were obtained from Iran University of Medical Sciences Research Ethics Committee prior to the launch of the study (code: 91/130/1985). This study is registered with the Iranian Registry of Clinical Trials: IRCT2013020810519N2.

An open pilot investigation to establish utility and safety of the pump was carried out in three patients for four weeks. Because of the lack of similar studies due to the novelty and a small number of patients, study on 30 people was conducted. So, we recruited 30 participants that suffered fecal incontinence and was managed by appendicostomy antegrade colon irrigation.

Inclusion criteria: patients older than 18 years with fecal incontinence and managed by appendicostomy antegrade colon irrigation.

Exclusion criteria were: noncompliance include to study, less than 2 months passed of appendicostomy

Pump ACIE for incontinence

operation, under 18 years, neuropsychiatric disease, significant cognitive impairment, active inflammatory bowel disease, and patients judged to have insufficient ability to accumulation data, history of bowel perforation, a complication occurred during the study.

We designed a randomized cross-over clinical trial study, involving two periods of four weeks treatment phases, ceaselessly. Period effect and carry-over effect eliminate by using a crossover study. All patients underwent a primary evaluation. Their histories include age, etiology of incontinence, duration of symptoms and antegrade colonic irrigation usage, length of bowel resection if done, recorded. Patients were randomized to one of the 2 groups A and B (random numbers generated by Excel function; Microsoft, Redmond, WA).

All 15 patients of group A, individually, used traditional method antegrade colonic irrigation for 4 weeks. Patients recorded certain variables for each time of colonic irrigation, including total toileting time (TT), the volume of water was used (V), infusion time duration (IT), and defecation starting time (DT). Then unceasing used a new method (rapid colon irrigation set) during 4 weeks, and same data was recorded by patients, including

total toileting time (TT), the volume of water was used (V), infusion time duration (IT), and defecation is starting time (DT).

All 15 patients of group B, individually, used a new method (rapid colon irrigation set) during 4 weeks. Patients recorded certain variables for each time of colonic irrigation, including total toileting time (TT), the volume of water was used (V), infusion time duration (IT), and defecation starting time (DT). Then unceasing used traditional method antegrade colon irrigation during 4 weeks. Same data was recorded by patients, include: total toileting time (TT), the volume of water was used (V), infusion time duration (IT), and defecation starting time (DT).

Also, after every four weeks, the degree of fecal incontinence was assessed by the Cleveland Clinic Florida Fecal Incontinence score (CCF_FIS). Those variables were similar for two methods. There was no interval between the two periods. At the end of the crossover periods, data analysis was performed by using SPSS V.16. Statistical tests, one-sample KS and T-test and bivariate correlation were used to analyze study and compare the results. $P < 0.05$ was considered significant.

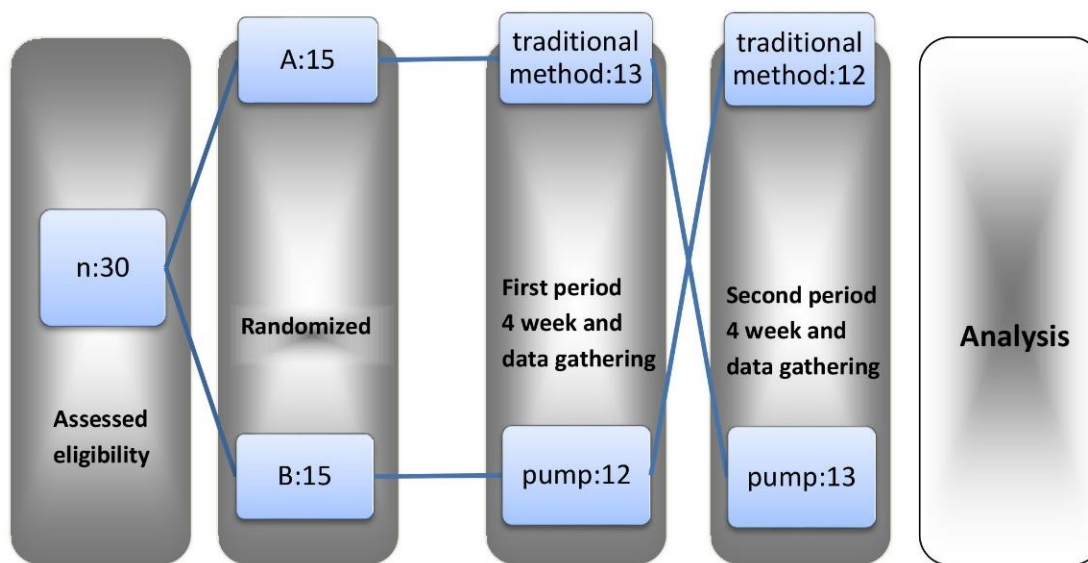


Figure 1. Consort flow diagram

Results

5 patients of the 30 eligible patients that included in the study did not complete the study due to loss of patient's desire. Therefore, 25 patients (14 male, 11 female) continued and finished two episodes. The mean

age of patients was 46.44 years (range 20 to 65). 56% of the cases were male. Meantime colonic irrigation that patients had done previously was 29.76 months (2-156). Rectal cancer surgery was the most etiology in 76% of patients (Table 1). Mean length of resected bowel in these patients was 23.1 cm. 59% of cases was doing

irrigation every two days, and other (41%) was doing every day in both methods. 3 patients (10%) had needed

to get help for irrigation performance.

Table 1. Distribution and etiology of patients

Etiology of incontinence	Frequency (Percent)
rectal cancer	19(76.0)
spinal injury	3(12.0)
Overflow	2(8.0)
congenital imperforate anus	1(4.0)
Total	25(100.0)

We collected data of irrigation time in three quantity: total toileting times (TT), time that water infusion was finished (infusion time-IT), length of time that defecation was started (defecation time-DT) for each two episodes

(Table 2). All patients had a reduction in toileting times. Traditional mean toileting time was 67minutes (40-240 min), versus pump-toileting time that was 24.6 minutes (15-60 min) ($P:0.00$).

Table 2. Total toileting times, Time that water infusion was finished, Length of time that defecation was started comparison for each two episodes

Variable	method	Mean(SD)	Min-max	P
Toileting time-TT (min)	Traditional	67(4.1)	40 – 240	0.000
	Pump	24.60(1.08)	15 - 60	
Infusion time-IT (min)	Traditional	31.20(1.37)	15 – 60	0.010
	Pump	7.60(3.8)	3 – 15	
Defecation time-DT (min)	Traditional	23(1.3)	10 – 60	0.000
	Pump	7.52(4.6)	2 – 15	
volume-V (ml)	Traditional	1712(8.20)	1000 – 4000	0.279
	Pump	1128(4.01)	700 - 2000	

In all cases mean water infusion times were reduced , mean infusion time in traditional method was 31.20 minutes (15-60 min), and in pump, method was 7.60 minutes (3-15 min) ($P:0.01$).

The time duration between starting of irrigation and starting of defecation was measured as defecation time (DT); mean DT in traditional method was 23 minutes (10-

60 min) versus 7.52 minutes (2-15 min) in pump method ($P:0.00$). The mean of volume that used for irrigation is recorded as V; 1712 ml in the traditional method and 1128 ml in pump method ($P:0.279$).

During the trial period, symptoms during or after defecation were recorded (Table 3). There was not any early complication in both methods.

Table 3. Symptoms during or after defecation

Symptom	Traditional method	Pump method
No	19	18
Abdominal cramps	4	3
Anorectal pain	1	0
Nausea	4	6
Sweating	1	1

Continence score was measured by CCF-FIS, so soiling stopped completely in 25 patients by pump whereas in traditional method 3 patients had soiling. But other criteria of CCF-FIS had different results. Finally mean CCF-FI score for the pump was 5.84 in compare of 6.24 for traditional method ($P:0.000$).

Patients scored their satisfaction between 1 and 10 in both methods. 21 patients (84%) were satisfied with their outcomes, and rate their satisfaction higher after using

pump compared without it. Three patients had the same satisfaction in both methods. And one patient was not satisfied with the pump compare traditional method.

Variables were analyzed with respect to sex, that all results include TT, IT, DT, V, CCF score in both genders were similar to previous except TT in males and IT in females. Mean TT for males in traditional method was 57.50 min versus 21.78 min in pump-method ($P:0.641$). Mean IT for females in traditional method were 33.18 min

versus 7.90 min in pump-method ($P:0.138$) (Table 4).

Table 4. Comparison of the results with respect to gender

Variable	Method	Male		Female	
		Mean	P	Mean	P
Toileting time-TT (min)	Traditional	57.5000		79.0909	
	Pump	21.7857	0.641	28.1818	0.000
Infusion time-IT (min)	Traditional	29.6429		33.1818	
	Pump	7.3571	0.038	7.9091	0.138
Defecation time-DT (min)	Traditional	20.3571		26.3636	
	Pump	5.5000	0.004	10.0909	0.020
Volume-V (ml)	Traditional	1707		1718	
	Pump	1100	0.890	1139	0.059
CCF-FIS	Traditional	5.9286		6.6364	
	Pump	5.5714	0.000	6.1818	0.001

In all cases TT, IT and DT were reduced. The volume of water was reduced in 13 patients, so in 12 cases did not change. Patients were divided into two groups. One of them (56%) had been using the irrigation for more than 12 months, and the other one (44%) had been using less than 12 months. The average of toileting time reduction (TTR) in the first group compare the second one, and the

average of defecation time reduction (DTR) in the first one compares the second one, indicate colon irrigation by pump was more effective in patients that previous colon irrigation has been less than 12 months (Table 5). But the average of infusion time reduction (ITR) in the first group was 20.85 min and in the second group was 27.09 min ($P:0.096$).

Table 5. The pump was more effective in patients that previous colon irrigation has been less than 12 months

Mean	First group (previous colon irrigation > 12 M)	Second group (previous colon irrigation ≤ 12 M)	P
TTR(min)	34.64	52.27	0.018
ITR (min)	20.85	27.09	0.096
DTR(min)	12.21	19.63	0.039
VR (ml)	2500	1009	0.001

Discussion

In all our cases, toileting times have reduced. Mean toileting time reduction was 42.40 min. It should be noted that this reduction is not only related to the time of infusion, and defecation time also has reduced. Mean infusion time reduction (ITR) was 15.48 min and mean defecation time was 23.59 min. so; defecation by pump starts earlier than another one due to more rapid bowel distension and more effective bowel peristalsis.

To our knowledge, this is the first study of its kind. Therefore, our results cannot be compared with those of others. In study of Sinha and colleagues, mean evacuation time had been 42 min (range 5-60) (18) and Teichman and colleagues, had recorded toileting time 8-50 min (44) and Yerkes and colleagues had recorded 20-60 min, although the mean age of patients in their study was 11.4 years (40). In a review of the literature, Graf and colleagues showed in the majority of patients; colonic evacuation occurred within 1 hour of enema

administration. Enema volume varied from 80 mL to over 1 L, with the administration taking from 5 to 60 min (39).

Volume and frequency of irrigation must be individualized to each patient. Tap water used alone or in combination included phosphate, saline, polyethylene glycol-electrolyte solution, phosphor soda, and Fleets. Sometimes, the combination is used to reduce the volume (14,19,21,44-48).

In different studies, the mean enema volume has been reported variously in the range of 500 to 1,500 ml (40,44,49-51). In Left-Colon Antegrade Continence Enema (LACE) patients, relatively small volumes of water were required to achieve bowel evacuation (29).

All our patients used tap water alone. And without pump, mean volume of water was 1712 ml (1000-4000). The mean volume of water reduction was about 550 ml but was not significant ($P:0.279$). This reduction was in 52% of cases, and in 48% (12 patients) did not change. In our study, patients were free for choosing the amount of water. They were unwilling to reduce the volume.

However, Yerkes and colleagues believed that there is no apparent relation between irrigation volume and the total time required to complete the irrigation, we think to reduce the volume of water can reduce the toileting time, Provided that this reduction does not adversely effect on fecal incontinence.

Side effects of the irrigation (leakage of water after irrigation, abdominal cramps, and distended abdomen) were reported in 61% of the patients by Koch (29,38). We detected no serious side effects such as abdominal cramps, anorectal pain, and nausea.

ACIE is known as fecal incontinence treatment that improve CCF-FIS and other continence scores (18,40). The effect of pump usage on CCF-FI score has a large variety such as the score in 12 patients improved, in 8 patients did not change, and in 5 patients declined. Anyway, mean CCF-FI score in both methods compared that improved by the pump. This improvement was significant ($P:0.000$). It seems that pump usage improves fecal incontinence, but longer follow up is needed.

According to our experiences as a referral colorectal center, 76% of patients in our study suffered fecal incontinence due to rectal cancer surgery.

Comparison of the two groups with more and less than 12 months previous colon irrigation showed pump was more effective in patients that previous colon irrigation has been less than 12 months.

Our study provides evidence for the first time that our novel method can facilitate and speed-up colon irrigation without any adverse effect on the outcome. So, this method allows patients to save time and gain the confidence to having the best quality of life. We recommend that by pump usage, the volume of water reduce, to reduce toileting time without any adverse effects. However, long-term follow up, for long-term pump's effects is necessary. And future studies with more samples would be performed.

References

1. Leigh RJ, Turnberg LA. Faecal incontinence: the unvoiced symptom. *The Lancet*. 1982;319(8285):1349-51.
2. Nelson R, Norton N, Cautley E, Furner S. Community-based prevalence of anal incontinence. *JAMA: the journal of the American Medical Association*. 1995;274(7):559-61.
3. Macmillan AK, Merrie AEH, Marshall RJ, Parry BR. The prevalence of fecal incontinence in community-dwelling adults: a systematic review of the literature. *Diseases of the colon & rectum*. 2004;47(8):1341-9.
4. Jorge JMN, Wexner SD. Etiology and management of fecal incontinence. *Diseases of the colon & rectum*. 1993;36(1):77-97.
5. Kamm MA. Fortnightly review: Faecal incontinence. *Bmj*. 1998;316(7130):528.
6. Nelson RL. Epidemiology of fecal incontinence. *Gastroenterology*. 2004;126:S3-S7.
7. Glickman S, Kamm M. Bowel dysfunction in spinal-cord-injury patients. *The Lancet*. 1996;347(9016):1651-3.
8. Malone PS, Wheeler RA, Williams JE. Continence in patients with spina bifida: long term results. *Archives of disease in childhood*. 1994;70(2):107-10.
9. Johanson J, Lafferty J. Epidemiology of fecal incontinence: the silent affliction. *The American journal of gastroenterology*. 1996;91(1):33.
10. Lahr C. Evaluation and treatment of incontinence. *Practical Gastroenterol*. 1988;12:27-35.
11. Lundby L, Duelund-Jakobsen J. Management of fecal incontinence after treatment for rectal cancer. *Current opinion in supportive and palliative care*. 2011;5(1):60.
12. Christensen P, Olsen N, Krogh K, Laurberg S. Scintigraphic assessment of colostomy irrigation. *Colorectal Disease*. 2002;4(5):326-31.
13. Dini D, Venturini M, Forno G, Bertelli G, Grandi G. Irrigation for colostomized cancer patients: a rational approach. *International journal of colorectal disease*. 1991;6(1):9-11.
14. Griffiths D, Malone P. The Malone antegrade continence enema. *Journal of pediatric surgery*. 1995;30(1):68-71.
15. Hughes S, Williams N. Continent colonic conduit for the treatment of faecal incontinence associated with disordered evacuation. *British journal of surgery*. 1995;82(10):1318-20.
16. O'bichere A, Sibbons P, Dore C, Green C, Phillips R. Experimental study of faecal continence and colostomy irrigation. *British journal of surgery*. 2002;87(7):902-8.
17. Gosselink M, Darby M, Zimmerman D, Smits A, Van Kessel I, Hop W, et al. Long-term follow-up of retrograde colonic irrigation for defaecation disturbances. *Colorectal Disease*. 2004;7(1):65-9.
18. Sinha CK, Grewal A, Ward HC. Antegrade continence enema (ACE): current practice. *Pediatric surgery international*. 2008;24(6):685-8.
19. Malone P, Ransley P, Kiely E. Preliminary report: the antegrade continence enema. *The Lancet*. 1990;336(8725):1217-8.
20. Curry J, Osborne A, Malone P. The MACE procedure: experience in the United Kingdom. *Journal of pediatric surgery*. 1999;34(2):338-40.
21. Levitt M, Soffer S, Pena A. Continent appendicostomy in the bowel management of fecally incontinent children. *Journal of pediatric surgery*. 1997;32(11):1630-3.

Pump ACIE for incontinence

22. Koivusalo A, Pakarinen M, Rintala RJ. Are cecal wrap and fixation necessary for antegrade colonic enema appendicostomy? *Journal of pediatric surgery*. 2006;41(2):323-6.
23. Casale P, Grady RW, Feng WC, Joyner BD, Mitchell ME. A novel approach to the laparoscopic antegrade continence enema procedure: intracorporeal and extracorporeal techniques. *The Journal of urology*. 2004;171(2):817-9.
24. Antao B, Ng J, Roberts J. Laparoscopic antegrade continence enema using a two-port technique. *Journal of Laparoendoscopic & Advanced Surgical Techniques*. 2006;16(2):168-73.
25. Rongen MJGM, Gerritsen A, Baeten CGMI. Cecal access for antegrade colon enemas in medically refractory slow-transit constipation. *Diseases of the colon & rectum*. 2001;44(11):1644-9.
26. Emmertsen KJ, Laurberg S. Bowel dysfunction after treatment for rectal cancer. *Acta Oncologica*. 2008;47(6):994-1003.
27. Yang CC, Stiens SA. Antegrade continence enema for the treatment of neurogenic constipation and fecal incontinence after spinal cord injury. *Archives of physical medicine and rehabilitation*. 2000;81(5):683-5.
28. TEICHMAN JMH, Harris J, CURRIE DM, BARBER DB. Malone antegrade continence enema for adults with neurogenic bowel disease. *The Journal of urology*. 1998;160(4):1278-81.
29. Churchill BM, De Ugarte DA, Atkinson JB. Left-colon antegrade continence enema (LACE) procedure for fecal incontinence. *Journal of pediatric surgery*. 2003;38(12):1778-80.
30. Krogh K, Laurberg S. Malone antegrade continence enema for faecal incontinence and constipation in adults. *British journal of surgery*. 1998;85(7):974-7.
31. Christensen P, Olsen N, Krogh K, Laurberg S. Scintigraphic assessment of antegrade colonic irrigation through an appendicostomy or a neoappendicostomy. *British journal of surgery*. 2002;89(10):1275-80.
32. Christensen P, Buntzen S, Krogh K, Laurberg S. Ileal neoappendicostomy for antegrade colonic irrigation. *British journal of surgery*. 2001;88(12):1637-8.
33. Koch SMP, Rietveld M, Govaert B, Van Gemert W, Baeten CGMI. Retrograde colonic irrigation for faecal incontinence after low anterior resection. *International journal of colorectal disease*. 2009;24(9):1019-22.
34. Lasser P, Dube P, Guillot J, Elias D. Pseudocontinent perineal colostomy following abdominoperineal resection: technique and findings in 49 patients. *European Journal of Surgical Oncology (EJSO)*. 2001;27(1):49-53.
35. Farroni N, Van den Bosch A, Haustermans K, Van Cutsem E, Moons P, D'hoore A, et al. Perineal colostomy with appendicostomy as an alternative for an abdominal colostomy: symptoms, functional status, quality of life, and perceived health. *Diseases of the colon & rectum*. 2007;50(6):817-24.
36. Abbas Orabi N, Vanwymersch T, Paterson H, Mauel E, Jamart J, Crispin B, et al. Total perineal reconstruction after abdominoperineal excision for rectal cancer: long-term results of dynamic graciloplasty with Malone appendicostomy. *Colorectal Disease*. 2011;13(4):406-13.
37. Portier G, Bonhomme N, Platonoff I, Lazorthes F. Use of Malone antegrade continence enema in patients with perineal colostomy after rectal resection. *Diseases of the colon & rectum*. 2005;48(3):499-503.
38. Koch SM, Uludağ Ö, El Naggat K, Van Gemert WG, Baeten CG. Colonic irrigation for defecation disorders after dynamic graciloplasty. *International journal of colorectal disease*. 2008;23(2):195-200.
39. Graf JL, Strear C, Bratton B, Housley HT, Jennings RW, Harrison MR, et al. The antegrade continence enema procedure: a review of the literature. *Journal of pediatric surgery*. 1998;33(8):1294-6.
40. Yerkes EB, Cain MP, King S, Brei T, Kaefer M, Casale AJ, et al. The Malone antegrade continence enema procedure: quality of life and family perspective. *The Journal of urology*. 2003;169(1):320-3.
41. Chang KJ, Erickson RA, Schandler S, Coye T, Moody C. Per-rectal pulsed irrigation versus per-oral colonic lavage for colonoscopy preparation: a randomized, controlled trial. *Gastrointestinal endoscopy*. 1991;37(4):444-8.
42. Fritscher-Ravens A, Mosse CA, Mills T, Ikeda K, Swain P. Colon cleaning during colonoscopy: a new mechanical cleaning device tested in a porcine model. *Gastrointestinal endoscopy*. 2006;63(1):141-3.
43. Obstein K. Advanced endoscopic technologies for colorectal cancer screening. 2012.
44. Teichman JMH, Zabihi N, Kraus SR, Harris JM, Barber DB. Long-term results for Malone antegrade continence enema for adults with neurogenic bowel disease. *Urology*. 2003;61(3):502-6.
45. Ellsworth P, Webb H, Crump J, Barraza M, Stevens P, Mesrobian HGJ. The Malone antegrade colonic enema enhances the quality of life in children undergoing urological incontinence procedures. *The Journal of urology*. 1996;155(4):1416-8.
46. Hill J, Stott S, MacLennan I. Antegrade enemas for the treatment of severe idiopathic constipation. *British journal of surgery*. 1994;81(10):1490-1.
47. Koyle MA, Kaji DM, Duque M, Wild J, Galansky SH. The Malone antegrade continence enema for neurogenic and structural fecal incontinence and constipation. *The Journal of urology*. 1995;154(2):759-61.

48. Webb HW, Barraza MA, Crump JM. Laparoscopic appendicostomy for management of fecal incontinence. *Journal of pediatric surgery.* 1997;32(3):457-8.
49. Meier DE, Foster ME, Guzzetta PC, Coln D. Antegrade continent enema management of chronic fecal incontinence in children. *Journal of pediatric surgery.* 1998;33(7):1149-52.
50. Gerharz EW, Vik V, Webb G, Leaver R, Shah PJR, Woodhouse CRJ. The value of the MACE (Malone antegrade colonic enema) procedure in adult patients. *Journal of the American College of Surgeons.* 1997;185(6):544-7.
51. Perez M, Lemelle J, Barthelme H, Marquand D, Schmitt M. Bowel management with antegrade colonic enema using a Malone or a Monti conduit: Clinical results. *European journal of pediatric surgery.* 2001;11(5):315-8.