

Comparison of Susceptibility Weighted Imaging and Time of Flight MR Angiography in the Detection of Intra-Arterial Thrombus in Acute Ischemic Stroke Patients

Ahmet Mesrur Halefoglul

Department of Radiology, Sisli Hamidiye Etfal Training and Research Hospital, University of Health Sciences, Istanbul, Turkey

Received: 14 May, 2019; Accepted: 18 Dec. 2019

Abstract- Susceptibility weighted imaging (SWI) and time of flight (TOF) magnetic resonance angiography (MRA) techniques can be used in the detection of major vessel occlusion. Our aim was to compare diagnostic accuracies of SWI and TOF MRA in the detection of arterial thrombotic occlusion in acute ischemic stroke patients. In this prospective study, we included 63 consecutive patients presenting with acute ischemic stroke symptoms in whom diagnoses were based on clinical findings and diffusion-weighted imaging (DWI) studies performed within 24 hours of the onset of symptoms. The susceptibility vessel sign (SVS) and TOF MRA findings of the patients were statistically evaluated in terms of detecting acute thrombotic arterial occlusion. In 50 out of 63 patients, SVS on SWI in major intracranial artery territories and a corresponding occlusion or severe stenosis of vessels on TOF MRA were detected with a concordance. In 5 patients, although the SVS was available, TOF MRA did not reveal any occlusion or stenosis in the corresponding artery territory. On the contrary, 3 patients showed stenosis or occlusion on TOF MRA in whom SVS was negative. Finally, in the remaining 5 patients with acute infarct, neither SVS on SWI nor occlusion or stenosis on TOF MRA were displayed. SVS on SWI yielded slightly higher sensitivity than TOF MRA in detecting intra-arterial thrombus in acute ischemic stroke patients. Although SWI and TOF MRA have similar diagnostic accuracies in the diagnosis of acute thrombotic occlusion in stroke patients, SWI has been found slightly superior to TOF MRA. © 2019 Tehran University of Medical Sciences. All rights reserved.

Acta Med Iran 2019;57(12):698-702.

Keywords: Ischemia; Magnetic resonance imaging; Susceptibility weighted imaging

Introduction

Susceptibility weighted imaging (SWI) is a long TE (time to echo), high resolution, fully velocity-compensated, three dimensional (3D) gradient-echo (GE) sequence that uses magnitude and filtered-phase information, both separately and in combination with each other, thus creating new sources of contrast (1). It is a relatively new MR sequence first described in 2004 by Haacke *et al.*, (2). This sequence accentuates magnetic susceptibility differences of various tissues, such as deoxyhemoglobin, hemosiderin, iron, and calcium. The susceptibility effect is highest in GE techniques at long echo times and higher field strengths. Although diffusion-weighted imaging (DWI) is still the mainstay imaging modality in the diagnosis of acute cerebral ischemia, SWI provides additional useful information in the evaluation and management of acute stroke patients. SWI can

reliably detect even small amounts of intracerebral and subarachnoid hemorrhages in an acute stage and can also reveal early hemorrhagic transformation in an infarcted area. It can demonstrate prominent veins in the vicinity of the ischemic brain region and indicates the extent of ischemic penumbra. SWI can also reveal susceptibility vessel sign (SVS) in different major intracranial artery territories and thus enables to detect the presence and accurate localization of intra-arterial thrombus in acute stroke patients. On the other hand, time of flight (TOF) magnetic resonance angiography (MRA) is a frequently used technique in the evaluation of acute ischemic stroke patients in order to reveal occluded or narrowed arteries, which are considered to be the main cause of acute stroke development. In this study, we aimed to investigate the diagnostic accuracies of SVS on SWI and TOF MRA findings in acute ischemic stroke patients and compared these results.

Corresponding Author: A.M. Halefoglul

Department of Radiology, Sisli Hamidiye Etfal Training and Research Hospital, University of Health Sciences, Istanbul, Turkey
Tel: +90 2123735000, Fax: +90 2122415015, E-mail address: halefoglul@hotmail.com

Materials and Methods

We performed a prospective study, including 63 consecutive patients consisting of 34 men (54 %) and 29 women (46 %). These patients had a mean age of 67.89 ± 15.76 years (26 years to 92 years). Our hospital's Institutional Research Ethics Committee approved the study, and we obtained informed consent from all of the patients. This study was carried out between March 2015 and April 2017. All patients in our study were admitted to the hospital, presenting with acute stroke symptoms and referred to DWI in less than 24 hours within the onset of symptoms. These patients also underwent routine whole-brain imaging, including SWI and TOF MRA examination immediately after DWI was performed. Two neuroradiologists carefully evaluated these images by reaching a consensus. All patients were examined using a 12-channel phased-array head coil on a 1.5-tesla clinical scanner (Avanto-SQ Engine, Siemens, Erlangen, Germany). The SWI sequence parameters were as below : TR (repetition time), 49 ms ; TE (echo time), 40 ms ; NEX (Number of excitations), 1; Flip angle (FA), 15 0; bandwidth, 80 kHz; slice thickness, 4 mm; Gap, 0.8; matrix size, 256 X 142. A TE of 40 ms was chosen to avoid phase aliasing, and a flip angle of 15 0 was used to avoid nulling of the signal from pial veins located within the cerebral spinal fluid (CSF) (7). The acquisition time was 1.36 min. With the use of iPAT factor-3. After post-processing nine to 12 mm. thick minIP slabs were generated. TOF MRA was also performed using a 3D sequence with the following parameters: TR (repetition time), 25 ms; TE (echo time), 7 ms; NEX (Number of excitations), 1; Flip angle (FA), 25; bandwidth, 100 kHz; FOV read, 180 mm; matrix size, 241 X 256; slice thickness, 0.64 mm; Gap, - 5.8 mm; and acquisition time; 5.56 min. These images were also reconstructed with a maximum intensity projection algorithm (MIP).

Based on the restricted diffusion areas on DWI in stroke patients, the infarcted area and related artery with respect to this territory were determined. One neuroradiologist evaluated susceptibility-weighted

images in order to detect SVS as a blooming artifact in the related major intracranial artery territory, which was blinded to TOF MRA findings of these patients. The other neuroradiologist who was blinded to findings obtained with SWI, carefully scrutinized TOF MRA images of patients to reveal occluded artery.

SPSS 15.0 for Windows program was used for statistical analysis. Descriptive statistics were given as numbers and percentages for categorical variables. Ratios of categorical variables in dependent groups were tested by McNemar analysis. The coherence of the tests was given by the number of Cohen's kappa. The statistical significance level of alpha was accepted as $P < 0.05$.

Results

In 55 out of 63 patients, we were able to detect SVS in the major intracranial arteries with 38 patients in the middle cerebral artery (MCA), 11 patients in the posterior cerebral artery (PCA) and 9 patients in the vertebral and/or PICA (posterior inferior cerebellar artery) territories. In 2 patients, both MCA and PCA and in 1 patient, both PCA and PICA SVS were present. In 55 patients showing a positive SVS on SWI, 50 of them displayed an equivalent on TOF MRA with either occlusion or severe stenosis of the corresponding arteries (Figure 1, Figure 2, Figure 3). 5 patients with SVS (4 patients in MCA, 1 patient in the vertebral artery) did not show any occlusion or stenosis on TOF MRA (Figure 4). 3 patients in whom SVS was negative, exhibited stenosis, or occlusion on TOF MRA (Figure 5). In the remaining 5 patients, even though they showed restricted diffusion on DWI, neither SVS nor occlusion or severe stenosis were found on SWI and TOF MRA, respectively (Figure 6).

SVS and TOF MRA were able to detect intra-arterial thrombus in acute stroke patients by 87.3 % and 84.1 %, respectively. There was no statistically significant difference in the rates of detection of intra-arterial thrombosis in patients with acute ischemic stroke ($P = 0.727$). Compliance between tests was moderate (kappa coefficient: 0.483).

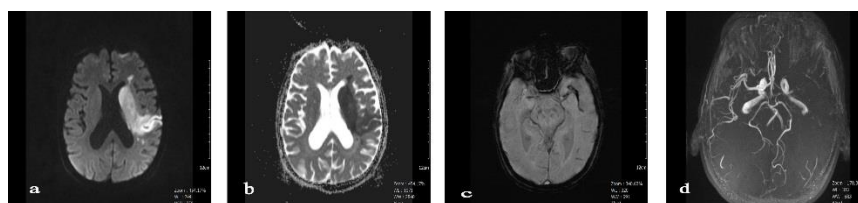


Figure 1. 67-year-old man with left lenticulo-striate acute infarct. a and b. Diffusion weighted and ADC map images show restricted diffusion in the left basal ganglion region presenting acute infarct. c. SWI magnitude image reveals blooming artifact consistent with SVS in the left MCA territory. d. TOF MRA axial MIP image shows absence of flow in the left MCA.

Comparison of susceptibility weighted imaging

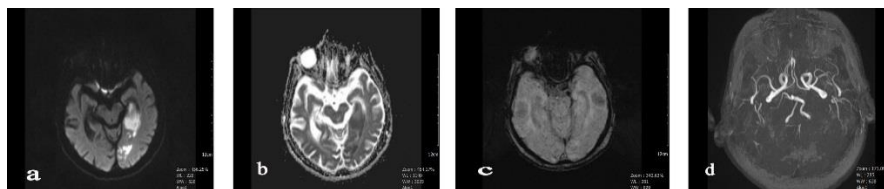


Figure 2. 84-year-old man with a left acute PCA infarct. a and b. Diffusion weighted and ADC map images show restricted diffusion in the left temporo-occipital lobe. C. SWI magnitude image shows SVS along the left PCA. D. TOF MRA axial MIP image reveals left PCA occlusion.

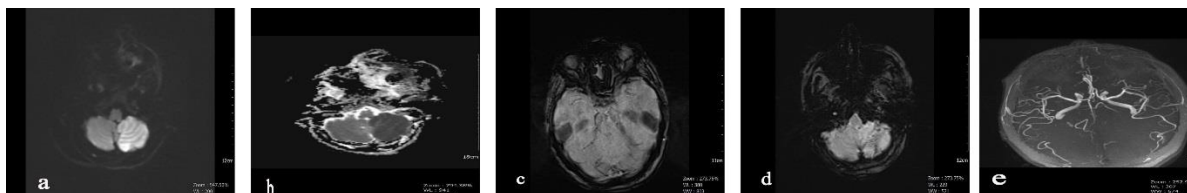


Figure 3. 57-year-old woman with acute left cerebellar infarct. a and b. Diffusion weighted and ADC map images, left cerebellar cortico-subcortical restricted diffusion consistent with the acute infarct. c. SWI magnitude image shows right PCA SVS. d. SWI magnitude image, another SVS is seen in the left vertebral and PICA territory. e. On TOF MRA axial MIP image, occlusion of both right PCA and left vertebral artery and PICA is present.

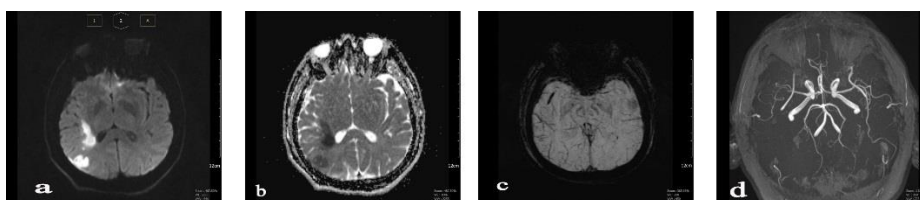


Figure 4. 50-year-old man presenting with acute right MCA infarct. a and b. Diffusion weighted and ADC map images reveal restricted diffusion in the right temporo-parietal region. c. SWI minIP image shows SVS along the right MCA. d. Contradicting the above findings, TOF MRA axial MIP image showing no stenosis, or occlusion along the right MCA distribution.

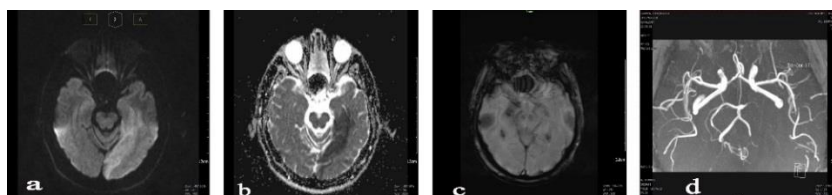


Figure 5. 64-year-old man with acute left PCA infarct. a and b. Diffusion weighted and ADC map images show restricted diffusion in the left temporo-occipital region. c. SWI magnitude image, SVS is not seen along the left ambient cistern. d. TOF MRA axial MIP image, clearly demonstrates absence of flow along the left PCA.

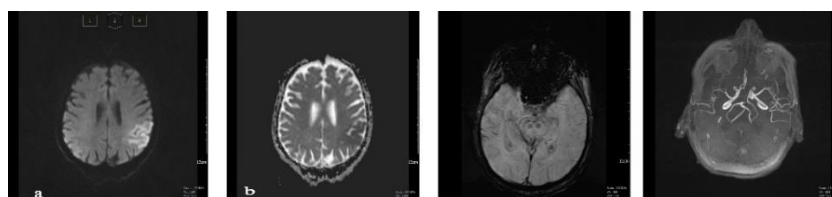


Figure 6. 72-year-old man presenting with acute left parietal infarct. a and b. Diffusion weighted and ADC map images reveal restricted diffusion in the left parietal region. c. SWI magnitude image, SVS is absent along the left MCA territory. d. TOF MRA axial MIP image shows no stenosis or occlusion along the left MCA distribution.

Discussion

Intracranial artery stenosis or occlusion arises from

either thrombotic or embolic origin, constituting the main causes of acute stroke development. Therefore accurate assessment and exact localization of intra-arterial thrombus play a crucial role in the determination

of therapeutic decisions. SWI has been found useful in the assessment and follow up of acute stroke patients. This imaging tool has the ability to give critical information regarding the presence of hemorrhage and also intra-arterial thrombotic occlusions that could both have significance in the assessment of acute stroke patients. TOF MRA is a frequently used imaging modality in the evaluation of acute stroke patients and can demonstrate stenosis or occlusion in the major intracranial arteries. The SVS is defined as the presence of hypointensity within the intracranial arteries in which the diameter of the hypointense vessel exceeds the contralateral vessel diameter (3). The diameter often exceeds the parent vessel due to the blooming artifact. The explanation to this is that SVS mainly arises from deoxyhemoglobin within the thrombus or some other component, like calcium may have a contribution to this appearance. On TOF MRA images, arterial severe stenosis or occlusion can be defined as loss of bright signal intensity in the arterial lumen and nonopacification of its distal parts on imaging. The demonstration and accurate localization of severe stenosis or occlusion of the artery may have prognostic and therapeutic implications in acute stroke patients (4). It has been postulated that SWI may allow the detection of distally located acute thrombi by revealing SVS, which may otherwise be missed on TOF MRA imaging (2,5). Thrombus is usually not picked up in partially occluded vessels on bright blood imaging sequences like TOF MRA examinations. TOF MRA is ascertained to be able to demonstrate only stenosis or occlusion and can not reveal the adjacent thrombus. Huang P. *et al.*, (6), in their study, used TOF MRA for the reference standard in the diagnosis of MCA occlusions and investigated the accuracy of SVS in the detection of intra-arterial thrombus. The SVS showed a significant correlation with MCA occlusion based on TOF MRA. In this study, all acute ischemic stroke patients with prominent negative veins and presenting positive SVSs exhibited poor outcomes. Lingegowda *et al.*, (7) retrospectively analyzed 48 patients who presented with acute ischemic stroke and had intra-arterial acute thrombus. They found a sensitivity of 82 % and specificity of 100 % for SVS for all acute major intracranial artery occlusions. They also revealed SVS as to be superior to hyperdense artery sign on computed tomography (CT) and hyperintense artery sign on fluid-attenuated inversion recovery (FLAIR) images in terms of revealing acute thrombus. Naggara O. *et al.* (8) demonstrated that thrombus location and length could be reliably assessed by SWI using SVS with a high concordance with the digital subtraction angiography

(DSA) method. They also postulated that SVS could be regarded as a relatively sensitive and specific marker of acute thrombus not only in MCA occlusion but also in occlusions of the internal carotid artery (ICA) and posterior circulation. In acute ischemic stroke patients, TOF MRA reveals thrombotic occlusion in arteries by demonstrating the absence of blood flow in the occluded vessel. But TOF MRA can not entirely delineate thrombus length, particularly if it is located distally in the vessel lumen. One major disadvantage of TOF MRA is its insensitivity towards slow flow or slow in-plane flow (9). This phenomenon limits the potential visualization of small arteries, such as M2 and M3 segments of MCA. A recently published study performed by Radbruch A. *et al.*, revealed that 3D SWI sequences based on SVS could be able to detect direct thrombus visualization in the occluded vessel (10). In this study, 87 out of 94 (92.6 %) acute ischemic stroke patients displayed a conspicuous SVS on SWI and in 72 out of 87 (76.6 %) of these patients, a good correlation was obtained with SVS on SWI and corresponding severe stenosis or occlusion of artery on TOF MRA. But in 15 patients with SVS on SWI, TOF MRA did not reveal any stenosis or occlusion in the corresponding arteries. They obtained a very high incidence of SVS on SWI when compared to the other studies and explained this situation as the increased field strength of the 3 T magnet they used, which provided an almost two-folded signal to noise ratio (SNR) than that of 1.5 T magnet (11). Therefore they formed the opinion that they may have detected SVSs which were not visible on most of the previous studies (3,12,13). They found similar sensitivities for SWI (97 %) and TOF MRA (96 %) in the detection of thrombotic occlusion in central intracranial arteries, whereas SWI was proven as being significantly sensitive than TOF MRA (84 % vs. 39 %, respectively) in revealing peripheral thrombotic occlusion. In our study, we were able to show SVS in 55 out of 63 patients, and in 50 patients with an SVS on SWI, their TOF MRA examinations revealed corresponding severe arterial stenosis or occlusion. Despite a slight superiority of SWI over TOF MRA, we can assert that there was a good correlation between these two imaging modalities in the detection of acute intra-arterial thrombus. We could not detect SVS in 8 patients despite the fact that restricted diffusion was found on their DWI. As mentioned in other studies, the reason for this is that SVS can be affected by small vessel diameters, because thrombi occluding peripheral arteries have smaller diameters than those in larger ones. Therefore vessel diameter is regarded as a predictor in the appearance of SVS. SWI can not be regarded as a replacement for TOF MRA in the setting of

Comparison of susceptibility weighted imaging

acute ischemic stroke because TOF MRA provides comprehensive peripheral vessel rarefaction, which is important in stroke classification and management (14). Instead, these techniques can be used as complementary to each other in the assessment of acute thrombotic occlusion in stroke patients.

Our study has several limitations. First, to begin with, our patient volume is relatively small. Secondly, although some of the patients in this study were referred to DSA for precise detection of acute intra-arterial thrombus, we did not use it as a reference standard. Thirdly, we usually evaluated acute stroke patients having a large volume of infarcted areas so that SVS could be clearly detected. Therefore there was a selection bias. In more peripheral arterial locations, detection of SVS on SWI and revealing the corresponding stenosis or occlusion of the related artery on TOF MRA might be extremely difficult, as discussed above. Probably further studies using 3T or more field strengths would be beneficial in order to obtain good results, especially in peripheral thrombotic arterial occlusions.

In acute ischemic stroke patients, SWI and TOF MRA should be used as complementary imaging modalities. SVS on SWI is a very useful sign that points to the location of the acute intra-arterial thrombus. In the majority of cases, TOF MRA confirms the diagnosis by revealing severe stenosis or occlusion in the corresponding artery.

References

1. Mittal S, Wu Z, Neelavalli J, Haacke EM. Susceptibility weighted imaging : Technical aspects and clinical applications, Part 2. *AJNR Am J Neuroradiol* 2009;30:232-52.
2. Haacke EM, Mittal S, Wu Z, Neelavalli J, Cheng YCN. Susceptibility weighted imaging : Technical aspects and clinical applications, Part 1. *AJNR Am J Neuroradiol* 2009;30:19-30.
3. Rovira A, Orellana P, Alvarez-Sabin J, Arenillas JF, Aymerich X, Grive E, et al. Hyperacute ischemic stroke : Middle cerebral artery susceptibility sign at echo planar gradient-echo MR imaging. *Radiology* 2004;232:466-73.
4. Hermier H, Nighoghossian N. Contribution of susceptibility-weighted imaging to acute stroke assessment. *Stroke* 2004;35:1989-94.
5. Chalela JA, Haymore JB, Ezzeddine MA, Davis LA, Warach S. The hypointense MCA sign. *Neurology* 2002;58:1470.
6. Huang P, Chen CH, Lin WC, Lin RT, Khor GT, Liu CK. Clinical applications of susceptibility weighted imaging in patients with major stroke. *J Neurol* 2012;259:1426-32.
7. Lingegowda D, Thomas B, Vaghela V, Hingwala DR, Kesavadas C, Sylaja PN. Susceptibility sign on susceptibility-weighted imaging in acute ischemic stroke. *Neurol India* 2012;60:160-4.
8. Naggara O, Raymond J, Ayllon MD, Al-Shareef F, Touze E, Chenoufi M, et al. T 2 * “ Susceptibility vessel sign ” demonstrates clot location and length in acute ischemic stroke. *PLoS One* 2013;8:e76727.
9. Ishimaru H, Ochi M, Morikawa M, Takahata H, Matsuoka Y, Koshiishi T, et al. Accuracy of pre- and postcontrast 3D time-of-flight MR angiography in patients with acute ischemic stroke:correlation with catheter angiography. *Am J Neuroradiol* 2007;28:923-6.
10. Radbruch A, Mucke J, Schweser F, Deistung A, Ringleb PA, Ziener CH, et al. Comparison of susceptibility weighted imaging and TOF-angiography for the detection of acute thrombi in acute stroke. *PLoS One* 2013;8:e63459.
11. Ladd ME. High-field-strength magnetic resonance : potential and limits. *Top Magn Reson Imaging* 2007;18:139-52.
12. Cho KH, Kim JS, Kwon SU, Cho AH, Kang DW. Significance of susceptibility sign on T 2 * - weighted gradient echo imaging for identification of stroke subtypes. *Stroke* 2005;36:2379-83.
13. Liebeskind DS, Sanossian N, Yong WH, Starkman S, Tsang MP, Moya AL, et al. CT and MRI early vessel signs reflect clot composition in acute stroke. *Stroke* 2011;42:1237-43.
14. Heiserman JE, Drayer BP, Keller PJ, Fram EK. Intracranial vascular stenosis and occlusion : evaluation with three-dimensional time-of-flight MR angiography. *Radiology* 1992;185:667-73.