

# Clinical and Histopathological Findings in Patients Who Underwent Splenectomy: A Ten-Year Study in Iran

Arash Dehghan, Nika Eskandari, Nakisa Niknejad

Department of Pathology, Besat Hospital, Hamedan University of Medical Sciences, Hamedan, Iran

Received: 04 Feb. 2020; Accepted: 10 Jun. 2020

**Abstract-** The description of histopathological features of spleen specimens in those are undergoing splenectomy is necessary and even vital for selecting the best patient's diagnostic and therapeutic management. However, in some cases, the histological findings of those with dramatic clinical presentation may be imperceptible and vice versa. What we did in the present study was to assess the clinical and histopathological findings as well as the main indications for splenectomy in a sample of Iranian affected population. This cross-sectional study was conducted on 616 spleen specimens following complete or partial splenectomy performed at pathology laboratory at Besat Hospital in Hamadan, Iran, between 2007 and 2017. Demographic characteristics, the main reasons for splenectomy, grading of trauma, and histopathological findings were retrospectively collected by reviewing the hospital recorded files and laboratory reports. The most common cause for splenectomy included trauma in 59.25%, followed by idiopathic thrombocytopenic purpura in 15.58% and symptomatic splenomegaly in 9.09%. The specimens were normal at 38.0%. Among those with lymphoma, the definitive diagnosis included diffused large B cell lymphoma in 42.85%, Hodgkin lymphoma in 42.85%, Follicular cell lymphoma in 9.52%, and Marginal cell lymphoma in 4.76%. Trauma and idiopathic thrombocytopenic purpura are the most common indications for splenectomy. Given the normality of the pathologic findings in more than one-third of patients undergoing splenectomy, closer attention to indications for this procedure through further evaluation of patients and predicting the outcome of the procedure is necessary.

© 2020 Tehran University of Medical Sciences. All rights reserved.

*Acta Med Iran* 2020;58(7):318-321.

**Keywords:** Splenectomy; Indication; Trauma

## Introduction

Complete or partial splenectomy, as an invasive or semi-invasive procedure, is a common procedure that considered as an elective surgery (following hematopoietic problems) or emergently following trauma or iatrogenic injuries (1,2). The first recorded splenectomy referred to 1549 by Adriano Zaccarelli (3). However, the minute evaluation of histopathological features, as well as its related inappropriate outcome, was not performed until 1920 (4). Also, due to the high likelihood of postoperative infection and its influence on the histological structure, the assessment of splenic histology is necessary to properly manage such adverse consequences. Unfortunately, in some situations, there is a significant disagreement between clinical condition and perceived findings in patients undergoing splenectomy (5). In some cases, the histological findings

of those with dramatic clinical presentation may be imperceptible (6). In addition, some patients whose spleens contain significant histological findings may be remained clinically undetectable or have no clinically detectable hematologic abnormalities (7). The existing paradox has drawn the attention of scientists to the point that, first of all, an overlap of clinical findings and histopathological assessments in determining the necessity for splenectomy is considered and second, in determining the indications for splenectomy, considerable attention is paid to avoid unnecessary surgeries to avoid its related adverse postoperative events. What we did in the present study was to assess the clinical and histopathological findings as well as the main indications for splenectomy in a sample of Iranian affected population.

## Materials and Methods

**Corresponding Author:** N. Niknejad

Department of Pathology, Besat Hospital, Hamedan University of Medical Sciences, Hamedan, Iran  
Tel: +98 9128118416, Fax: +98 8132640064, E-mail address: Dr.nakisa\_niknejad@yahoo.com

This cross-sectional study was conducted on all spleen specimens following complete or partial splenectomy performed at pathology laboratory at Besat Hospital in Hamadan, Iran, between 2007 and 2017. Following approval of the study protocol by Hamadan University of Medical Sciences, all baseline variables of the patients including demographic characteristics, the main reasons for splenectomy (trauma, idiopathic thrombocytopenic purpura (ITP), symptomatic splenomegaly, hypersplenism, spherocytosis, major thalassemia, glucose-6-phosphate dehydrogenase (G6PD) disorder, etc.), grading of trauma, and histopathological findings were retrospectively collected by reviewing the hospital recorded files and laboratory reports. The results were presented as mean±standard deviation (SD) for quantitative variables and were summarized by absolute frequencies and percentages for categorical variables. For the statistical analysis, the statistical software SPSS version 16.0 for windows (SPSS Inc., Chicago, IL) was used.

## Results

In total, 616 spleen specimens (388 from male patients and 228 from female patients) were assessed. The average age of participants was  $32.16 \pm 19.28$  years ranged widely from 1 to 90 years, with the age peak age

of 20 to 30 years (Figure 1).

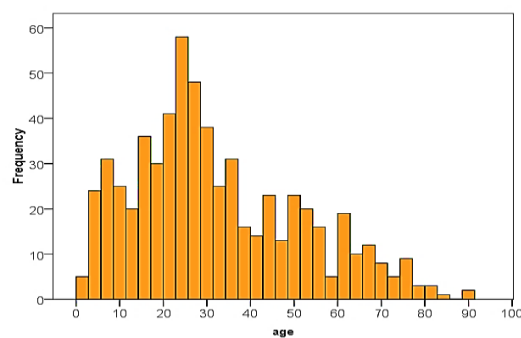


Figure 1. Age distribution in patients undergoing splenectomy

As shown in Table 1, the most common cause for hospitalization and splenectomy included trauma (59.25%) followed by ITP (15.58%) and symptomatic splenomegaly (9.09%). The histopathological findings in non-traumatic cases are summarized in Table 2. In this regard, the specimens were normal in 38.0%, while other common pathological findings included ITP in 31.3%, extramedullary hematopoiesis in 13.28%, and lymphoma in 7.9%. Among those with lymphoma, the definitive diagnosis included diffused large B cell lymphoma in 42.85%, Hodgkin lymphoma in 42.85%, Follicular cell lymphoma in 9.52%, and Marginal cell lymphoma in 4.76%.

Table 1. Reasons for splenectomy

Trauma	365 (59.25)
ITP	96 (15.58)
Symptomatic splenomegaly	56 (9.09)
Hypersplenism	9 (1.46)
Spherocytosis	5 (0.81)
Major thalassemia	3 (0.49)
G6PD deficiency	2 (0.32)
Others	80 (12.99)

Table 2. The histopathological findings in non-traumatic cases for splenectomy

Normal	101 (38.0)
ITP	83 (31.3)
Extramedullary hematopoiesis	35 (13.28)
lymphoma	21 (7.9)
Hypersplenism	5 (1.9)
Myelofibrosis	5 (1.9)
Simple cyst	4 (1.5)
Spleen tuberculosis	3 (1.1)
Metastasis	2 (0.8)
Spleen abscess	2 (0.8)
Hemangioma	2 (0.8)
Metabolic disorders (gaucher disease)	1 (0.4)
Hydatid cyst	1 (0.4)
Angiosarcoma	1 (0.4)

## Discussion

The description of histopathological features of spleen specimens in those undergoing splenectomy is necessary and even vital for selecting the best patient's diagnostic and therapeutic management. In this regard, in addition to the assessment of clinical features and the reasons for splenectomy, matching clinical and pathological findings is also essential because, in many cases, there is heterogeneity between these findings, and it may be possible to divert the minds of specialists. As shown in the present study, about 38.0% of specimens, which were candidates for splenectomy were normal with respect to histological features. Regarding normal histopathological conditions according to the initial reason for splenectomy, we showed normal histopathology reports in a significant number of patients with underlying etiologic symptomatic such as splenomegaly, trauma to spleen, ITP, hypersplenism, spherocytosis, G6PD, or major thalassemia had normal clinical situations. Besides, the presence of the normal clinical condition is never justified by abnormal histopathological findings in these patients. Thus, clinical findings should not be a criterion for evaluating the severity of pathologic involvement in these patients and vice versa. This mismatching is more important in cases where there is a need to differentiate between benign and malignant lesions due to significant differences in diagnostic and therapeutic approaches. In this regard, the use of other diagnostic methods such as imaging has also been recommended in conjunction with biopsy. In some animal studies, it was shown that those subjects with severe clinical features such as gross splenic and liver masses had the benign pathological feature, however, in some asymptomatic cases, the pieces of evidence of malignancy in either the liver or the spleen were found (8). A similar feature is founded in human studies. As indicated by Hunaina Al-Kindi and colleagues (9), of the 17 cases of splenectomy, 82.3% were normal. In another case study by Tunçyürek *et al.*, (10), a case was described with no evident splenomegaly in the abdominal CT, but with the final diagnosis of progressive diffuse large B-cell lymphoma. Therefore, clinical features should never be judged for the progression of the disease or the severity of its pathological changes. Also, significant pathological changes are not always accompanied by significant changes in the pathological face of the disease. Fortunately, as shown in our survey, in critical conditions such as hematopoietic disorders or malignancies, incompatibility between clinical and

pathological findings is rarely seen, and this heterogeneity is more seen in benign conditions.

As clearly shown in our study, the most common reasons for splenectomy included trauma in more than half of the cases followed by ITP and symptomatic splenomegaly with any diagnosis. Rupturing or blunt trauma is the most common cause of splenectomy in almost all reports. As previously shown by Rose *et al.*, (11), trauma was accounted for 41.5% of all splenectomies, while hematologic malignancy in 15.4%, cytopenia in 15.6%, iatrogenic causes in 8.1%, and portal hypertension in 2.3%. In another study by Meshikheset *et al.*, (12), the most common indication was trauma in 43.6%, followed by hematological reasons in 25.5%, which were mainly in sickle cell disease patients. Regarding absolute indications for splenectomy, splenic trauma is in the top of reasons that might be accompanied by acute or delayed rupture of the spleen (evident by subcapsular hematoma from trauma). Other indications for splenectomy include splenic abscess or cysts frequently due to tuberculosis infection, dyscrasias and reticuloendothelial disorders, and different neoplasms. As also shown in our study, thrombocytopenic disorders are at the second level of causes for splenectomy. Splenomegaly is commonly indicated for conditions such as ITP, thrombotic thrombocytopenic purpura (TTP), and hereditary spherocytosis. Of these, ITP is the most common indication for elective splenectomy (13). Splenectomy has been indicated for treating ITP since 1913 (14); however, its long-term safety is not well elucidated. It is now believed that splenectomy should be indicated in patients with ITP following failed response to steroid treatment that may be observed only in 7% of affected patients (15,16). Overall, trauma (blunt or ruptured) followed by ITP should always be considered as the most common etiologies for splenectomy, but determining the factors which favorite predicting outcome and hood response to this procedure in such etiologies should also be considered that was not assessed in the present study.

As the final conclusion, the main indications for splenectomy include trauma followed by ITP and symptomatic splenomegaly. Interestingly, about 38.0% of specimens that were a candidate for splenectomy were normal with respect to histological features, and thus significant pathological changes are not always accompanied by significant changes in the pathological face in those who underwent splenectomy for any reason.

## Acknowledgments

The authors thank all those who helped them writing this paper.

## References

- Esposito F, Noviello A, Moles N, Cantore N, Baiamonte M, Coppola Bottazzi E, et al. Partial splenectomy: A case series and systematic review of the literature. *Ann Hepatobiliary Pancreat Surg* 2018;22:116-27.
- Costi R, Castro Ruiz C, Romboli A, Wind P, Violi V, Zarzavadjian Le Bian A. Partial splenectomy: Who, when and how. A systematic review of the 2130 published cases. *J Pediatr Surg* 2019;54:1527-38.
- Wilkins BS. The spleen. *Br J Hematol* 2002;117:265-74.
- Bickenbach KA, Gonen M, Labow DM, Strong V, Heaney ML, Zelenetz AD, Coit DG. Indications for and efficacy of splenectomy for hematological disorders. *Br J Surg* 2013;100:794-800.
- Kraus MD. Splenic histology and histopathology: an update. *Semin Diagn Pathol* 2003;20:84-93.
- Nagarjuna Chary R, Ather F, Kazi W H, KumudaChalam P, Ibraheem J M. Spectrum of splenic pathology at a single center. *Indian J Pathol Oncol* 2016;3:622-626.
- Mesa RA, Li CY, Schroeder G, Tefferi A. Clinical correlates of splenic histopathology and splenic karyotype in myelofibrosis with myeloid metaplasia. *Blood* 2001;97:3665-7.
- Leyva FJ, Loughin CA, Dewey CW, Marino DJ, Akerman M, Lesser ML. Histopathologic characteristics of biopsies from dogs undergoing surgery with concurrent gross splenic and hepatic masses: 125 cases (2012-2016). *BMC Res Notes* 2018;11:122.
- Al-Kindi H, Devi L, George M. Splenic pathology in traumatic rupture of the spleen: a five year study. *Oman Med J* 2009;24:81-3.
- Tunçyürek Ö, Tunçyürek P, Ertekin E, Gök M, Nevai EH, Döger FK, et al. Pathological rupture of the normal spleen: Review with the literature. *Int J Surg Case Rep* 2016;26:163-5.
- Rose AT, Newman MI, Debelak J, Pinson CW, Morris JA Jr, Harley DD, et al. The incidence of splenectomy is decreasing: lessons learned from trauma experience. *Am Surg* 2000;66:481-6.
- Meshikhes AW, Mubarek MA, Abu-Alrahi AI, Al-Saif OH. The pattern of indications and complications of splenectomy in Eastern Saudi Arabia. *Saudi Med J* 2004;25:1892-5.
- Li Y, Zhang D, Hua F, Gao S, Wu Y, Xu J. Factors associated with the effect of open splenectomy for immune thrombocytopenic purpura. *Eur J Haematol* 2017;98:44-51.
- Coon W W. Splenectomy for idiopathic thrombocytopenic purpura. *Surg Gynecol Obstet* 1987;164:225-9.
- Kojouri K, Vesely SK, Terrell DR, George JN. Splenectomy for adult patients with idiopathic thrombocytopenic purpura: a systematic review to assess long-term platelet count responses, prediction of response, and surgical complications. *Blood* 2004;104:2623-34.
- Najean Y, Dufour VJD, Toubert ME. The site of platelet destruction in thrombocytopenic purpura as a predictive index of the efficacy of splenectomy. *Br J Haematol* 1992;79:271-6.