

# Primary Localization of a Hydatid Cyst in the Pancreas via Laparoscopic Treatment: A Case Report

Adeleh Hashemi Fard<sup>1,2</sup>, Hormoz Hoseinpour Deyrestani<sup>1,2</sup>, Hamed Golmohamadi<sup>1,2</sup>, Alireza Rezapanah<sup>1,2</sup>

<sup>1</sup> Surgical Oncology Research Center, Emam Reza Hospital, Mashhad University of Medical Sciences, Mashhad, Iran

<sup>2</sup> Faculty of Medicine, Mashhad University of Medical Sciences, Mashhad, Iran

Received: 19 Jul. 2020; Accepted: 14 Jan. 2021

**Abstract-** Hydatid disease is mainly because of the *Echinococcus granulosus* at the larval stage. The liver and lung are its most consequences. The pancreatic hydatid cyst (PHC) incidence is very low (0.14%-2%). A 55-year-old female patient presented with epigastric pain for the last one year that the pain did not continue but during one months ago suffered continually. In physical examination, there was not any abdominal bulb, tenderness and rebound tenderness. A 54×59 mm cystic structure was observed by ultrasonography (USG) and Contrast-enhanced Computed Tomography (CT) in the pancreatic body with stone in the gallbladder. Amylase, lipase, and LFT levels were normal. The Anti-hydatid antibody was positive. During laparoscopic exploration, a hydatid cyst was found. Partial cystectomy with external drainage and cholecystectomy was performed once irrigation with scolicedal agent and evacuation of cystic contents was conducted. Histopathological biopsy reported Hydatid cyst. A pancreatic, hepatic cyst is a rare event. Hematogenous is the most common spread way. Cysts in the pancreatic head could be found with obstructive jaundice. Usually, cysts in the body and tail are known to be asymptomatic. USG, CT, and Hydatid serology are useful with the clinical diagnosis as well as monitoring the recurrence. An exploration via surgery is an option that includes pericystectomy, partial cystectomy with/without external drainage or omentopexy, marsupialization, or cysto-enterostomy, which is done. What makes this case unique is the laparoscopic method that we used instead of open surgery, which is a treatment of choice. The recommendation is pre-operative and postoperative antihelminthic (Albendazole). PHC could be present as pseudocyst or cystic neoplasm of the pancreas. For patients with endemic regions and laparoscopic surgery, differential diagnosis of the cystic pancreatic lesion should be noticed. Common surgery approach could be considered for such patients.

© 2021 Tehran University of Medical Sciences. All rights reserved.

*Acta Med Iran* 2021;59(4):232-235.

**Keywords:** Hydatid cyst; Pancreatic cyst; Laparoscopy

## Introduction

Hydatid disease is due to infection by the tapeworm *Echinococcus granulosus* (hydatid worm) in its larval or cyst stage. The tapeworm lives in canids. While eating sheep viscera, which includes hydatid cysts, they are infected. Scolices, which are in the cysts, stick to the small intestine of dogs and become adult taenia, which adheres to the intestinal wall. Worms shed approximately 500 ova into the bowel. Grass and farmland are contaminated by the infected ova-containing feces of dogs, and intermediate hosts such as sheep, cattle, pigs,

and humans ingest the ova. The ova contain chitinous envelopes dissolved by gastric juice. The liberated ovum then burrows through the intestinal mucosa, and the portal vein will carry it to the liver, where it develops into an adult cyst. Cysts are mostly caught in the hepatic sinusoids, and hence 70% of hydatid cysts shape in the liver. The liver is where a few ova pass through and are held up in the pulmonary capillary bed or enter the systemic circulation, where forming cysts in the spleen, brain, lung, or bones (1,2).

Hydatid cysts could be observed in almost any site of the body, but the most common organs are the liver (50% -

**Corresponding Author:** A. Rezapanah

Surgical Oncology Research Center, Emam Reza Hospital, Mashhad University of Medical Sciences, Mashhad, Iran  
Tel: +98 9155003756, Fax: +98 21 42910703, E-mail address: rezapanaha1@mums.ac.ir

Copyright © 2021 Tehran University of Medical Sciences. Published by Tehran University of Medical Sciences  
This work is licensed under a Creative Commons Attribution-NonCommercial 4.0 International license (<https://creativecommons.org/licenses/by-nc/4.0/>). Non-commercial uses of the work are permitted, provided the original work is properly cited

77%), lung (15%-47%), spleen (0.5%-8%), and kidney (2%-4%). In this paper, an epigastric pain along with cystic pancreatic mass case will be presented (3).

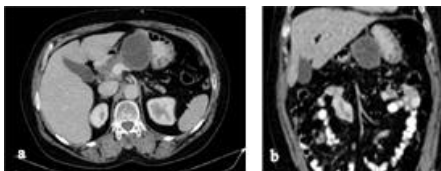
## Case Report

A 55-year-old female patient presented with epigastric pain complaint by chief for one year. Onset pain was observed to be insidious, discontinuous, non-progressive, radiating to the back that was not related to feeding. The patient had nausea and anorexia. There is not any abdominal tenderness or rebound tenderness based on the physical examination.

Normal baseline hematological as well as biochemical features were reported. Serum amylase of 59 U/L and lipase of 25 U/L were non-diagnostic for acute pancreatitis. However, previous serum amylase and lipase within normal range were found at the symptoms onset (one year earlier). Chest X-ray was found to be in normal range. A cystic structure in the body as well as tail region of the pancreas (with a size of 5.4×5.9 cm) was observed based on ultrasonography of the abdomen. Some stones were noted in the gallbladder without thickening of the wall of the gallbladder. Also mass lesion was observed.

Contrasting round to oval cystic lesion with a size of 42×60 mm was reported by contrast enhanced CT abdomen. The location was observed to be in the epigastric region close to pancreatic body with some compression over stomach adjacent posterior wall and the first part of deudunom with slightest adjacent fat stranding with contrasting peripherally enhancing margins (Figure 1a).

The differential diagnosis from radiological point of view was between a pseudopancreatic cyst (pancreatic cyst-like) and a cystic pancreatic neoplasm (Figure 1b). The patient had no trauma or pancreatitis history, and therefore it is less likely to be a pseudocyst case.



**Figure 1.** a: Computed tomography scan view of lesion, b: Computed tomography scan of lesion-coronal section

A cystic neoplasm of the pancreas was the other differential diagnosis. The cyst site as well as the analysis of the cystic fluid aspirate (low CEA, low Amylase, mucin negative) favoured serous cystic neoplasm (SCN),

however the SCN characteristic via radiological findings was not observed by the CT.

A decision was eventually made to explore the case via the laparoscopic incision. The patient's symptoms were actually the main reason for operating. Unless the initial clinical suspicion was a hydatid cyst, but a SCN of the pancreas was one of clinical suspicion though the CT scan did not show any characteristic findings. We enter the abdomen through 4 trocars. Intraoperatively, after we cut the gastrocolic ligament, we found a 5×6 cm cystic structure originating from the upper border, resulting in pushing the stomach forward by the pancreas body.

Since we made sure to aspirate the cyst first with a syringe, intraoperative spillage from the cyst was minimal.

Clear fluid was shown in the aspiration of the cyst. The cyst was opened, and then we observed a germinal membrane. The cyst was then injected with a scolicidal agent via 0.5% Cetrimide solution. After packing the operative field with Cetrimide soaked sponges, the contents evacuated. The abdomen was irrigated using scolicidal agent. Partial cystectomy, as well as external drainage of the residual cavity, were done. No communication with the pancreatic duct was observed. Then we set another trocar up for cholecystectomy. As well as we set 2 drains, one drain in the cavity of the cyst and another one under the liver.

Hydatid cyst was confirmed by postoperative histopathological analysis. The result of ELISA found to be positive for Echinococcal antigens via post-operatively. The postoperative drain output was also very little. On postoperative day-3, the drains were removed. Oral Albendazole tablets (10 mg/kg/day) were prescribed for eight weeks, and the patient was discharged.

The results of the peri-operative photograph indicate 1. The cyst has been opened after irrigation with scolicidal agent and evacuation of the contents, 2. The germinal membrane is being removed.

## Discussion

The incidence of pancreatic hydatid cysts (PHC) are low, with a reporting frequency of 0.14-2% (4). PHCs are mostly solitary (90%-91%) and unevenly spread over the whole head (50%-58%), body (24%-34%), and tail (16%-19%) (5). Hematogenous dissemination is assumed to be the popular type of spread towards to the pancreas. Here are the alternative probable spread types of cystic elements to the pancreas: lymphatic spread from the intestinal mucosa, described passage through the biliary system, direct passage through the pancreatic veins, and

retroperitoneal dissemination (4,5).

The site of the cyst within the pancreas plays an important role when it comes to clinical presentation. For example, if the cysts are located in the head, it could be presented as obstructive jaundice because of external compression of the common bile duct and masquerade as a choledochal cyst. On the other hand, if the site of the cysts is in the body and tail of the pancreas, they are often asymptomatic unless they grow and get bigger to be known as an abdominal lump or cause symptoms because of compression of adjacent structures such as epigastric pain, nausea, and vomiting. It is very rare that splenomegaly and portal hypertension is present as a result of the site of the cysts in the pancreatic tail (3-8).

Some complications have been described, such as cholangitis, rupture into the biliary tree or peritoneal cavity, pancreatic fistula, recurrent pancreatitis, and abscess (9).

For the aim of diagnosing a pancreatic cyst, imaging modalities commonly are used including Ultrasonography (USG), Computed Tomography (CT) and Magnetic Resonance Imaging (MRI). It is known that Abdominal USG is a diagnostic test with high sensitivity for Hydatid Cyst with floating membranes, hydatid sand and daughter cysts. However, the sensitivity is dropped because of retroperitoneal site and bowel gas in case of PHCs. When an undulating membrane and multiple daughter cysts within a mother cyst are present, the diagnosis on CT and MRI is suggested. To exclude pancreatic cystic neoplasms and pseudocyst of pancreas, Endoscopic Ultrasound (EUS) guided aspiration of pancreatic cystic fluid and cytological/biochemical evaluation could be helpful. If the site of the pancreatic cyst is in the pancreas head and/or causing ductal compression, Magnetic Resonance Cholangio-Pancreatography (MRCP) helps in delineating the biliary tree and pancreatic duct. For cholangitis or pancreatitis secondary to biliary/pancreatic ductal compression by PHCs, Endoscopic Retrograde Cholangio-Pancreatography (ERCP) is suitable for palliative stenting. To detect particular serum antibodies as well as circulating echinococcal antigens, indirect hemagglutination assay, immunoelectrophoresis, enzyme linked immunosorbent assay, complement fixation test and immunofluorescence assay could be used. These tests are helpful even in follow-up monitoring. In more than 85% of cases, Enzyme-linked immunosorbent assay for Echinococcal antigens is positive. The radiological finding described for hydatid cysts is usually not present, which is the case presented in this paper too (3-5,11-15)

This makes it difficult to distinguish between PHCs and typical cystic lesions of the pancreas, such as pseudocysts and benign or malignant cystic neoplasms of the pancreas. However, the differential diagnosis of PHCs should be noted in cystic pancreatic lesions in patients from endemic areas (4,5,16).

In diagnosing equivocal cases, Percutaneous or Endoscopic ultrasonography-guided Fine needle aspiration cytology could be helpful. However, to avoid anaphylactic reaction and peritoneal seeding in case of spillage or perforation, prophylactic antihelminthics should be started (16).

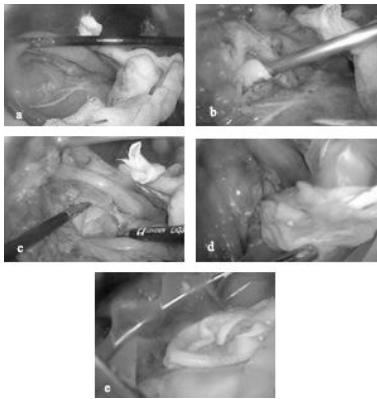
It is usually impossible to come up with a final decision for diagnosis without considering surgical exploration conservative approaches such as Puncture-Aspiration-Injection-Respiration (PAIR) or direct percutaneous catheterization along with medical therapy for patients not suitable for surgical intervention (3-5,17). But hydatid cyst should be considered to investigate the main reason of a rare location or an unanticipated clinical situation. This is especially important in endemic regions and rural areas. Hence, needle aspiration/biopsy should not be considered when typical findings are present, and the better approach to come up with a definitive diagnosis is an MRI scan (18).

Open surgery is the treatment of choice; however, the exact procedure is associated with the cyst location. If the site of the cysts is in the tail and body/neck of the pancreas, distal pancreatectomy and central pancreatectomy are appropriate. An alternative procedure would be the laparoscopic evacuation of the cyst with omentoplasty via a 10 mm trocar, which is what is used in our case. Although the choice treatment is open surgery, the laparoscopic method has some benefits such as less chance of wound infection and lower length of hospitalization (3-5).

Throughout the procedure, care should be taken to pack the operative area with sponges soaked in scolicidal agents such as 0.5% Cetrimide or 20% Hypertonic saline and avoid spillage of the cyst contents. The scolicidal agents must be used to irrigate the cyst. For the preoperatively diagnosed patients, prophylactic antihelminthic agents (Albendazole 10 mg/kg/day) should be taken for 2-4 weeks and continued for at least four weeks post-operatively. This is to decrease the risk of 1. Anaphylactic reaction in the presence of spillage or perforation, and 2. Postoperative recurrence (3,19).

The incidence of primary hydatid cyst of the pancreas is too low; however, what makes this case interesting is the laparoscopic method we used (Figure 2a-e). Also, the motivation for presenting this case is to emphasize that

hydatid cyst could show as more common cystic lesions of the pancreas. This may not be considered as a differential diagnosis for clinicians who have not come across a pancreatic hydatid cyst. A pancreatic hydatid cyst as the differential diagnosis should always be considered in patients from endemic areas (3).



**Figure 2.** a: Intra-operative view of bulging cyst, b: View of germinal layer of the cyst, intra-operative, c: View of germinal layer of the cyst, intra-operative after exposure, d: View of germinal layer of the cyst, intra-operative while being removed, e: View of germinal layer of the cyst, intra-operative after removal

PHCs could show as more common lesions of the pancreas such as pseudocyst or cystic pancreatic neoplasms. In case of cystic pancreatic mass in patients from endemic areas, PHCs should always be noted as a differential diagnosis. Also, laparoscopic surgery could be considered a useful method.

## References

- Bhagani S, Cropley I. The Liver in Infections. In: Dooley JS, Lok AS, Garcia-Tsao G, Pinzani M, eds. *Sherlock's Diseases of the Liver and Biliary System*. 13<sup>th</sup> ed. USA: John Wiley & Sons, 2019.
- Ashfaq H, Obaid O, Shafi S, Ul Hassan M, Rather A. Hydatid disease of liver and disseminated hydatidosis: anatomical, microbiological and radiological perspective. *Int J Res Med Sci* 2013;1:101-3.
- Ahmed Z, Chhabra S, Massey A, Vij V, Yadav R, Bugalia R, et al. Primary hydatid cyst of pancreas: Case report and review of literature. *Int J Surg Case Rep* 2016;27:74-7.
- Shah OJ, Robbani I, Zargar SA, Yattoo GN, Shah P, Ali S, et al. Hydatid cyst of the pancreas. An experience with six cases. *JOP* 2010;11:575-81.
- Akbulut S, Yavuz R, Sogutcu N, Kaya B, Hatipoglu S, Senol A, et al. Hydatid cyst of the pancreas: report of an undiagnosed case of pancreatic hydatid cyst and brief literature review. *World J Gastrointest Surg* 2014;6:190-200.
- Mandelia A, Wahal A, Solanki S, Srinivas M, Bhatnagar V. Pancreatic hydatid cyst masquerading as a choledochal cyst. *J Pediatr Surg* 2012;47:e41-4.
- Turkyilmaz Z, Kapisiz A, K Sonmez K, Karabulut R, Basaklar AC. Obstructive jaundice resulted from hydatid cyst of pancreatic head. *Hippokratia* 2013;17:378-9.
- Szanto P, Goian L, Al Hajar N, Badea R, Seicean A, MD, Manciu D, et al. Hydatid cyst of the pancreas causing portal hypertension. *Maedica (Buchar)* 2010;5:139-41.
- Chinya A, Khanolkar A, Kumar J, Sinha SHK. Isolated hydatid cyst of the pancreas masquerading as pancreatic pseudocyst. *BMJ Case Rep* 2015;2015:bcr2015211307.
- Sharma S, Sarin H, Guleria M, Agrawal K. Endoscopic ultrasound-guided FNA: emerging technique to diagnose hydatid cyst of pancreas. *J Cytol* 2015;32:211-2.
- Lewall DB, McCorkell SJ. Hepatic echinococcal cysts: sonographic appearance and classification. *Radiology* 1985;155:773-5.
- Masoodi MI, Nabi G, Kumar R, Lone MA, Khan BA, Naseer Al Sayari K. Hydatid cyst of the pancreas: a case report and brief review. *Turk J Gastroenterol* 2011;22:430-2.
- Agrawal S, Parag P. Hydatid cyst of head of pancreas mimicking choledochal cyst. *BMJ Case Rep* 2011;2011:bcr0420114087.
- Sbihi Y, Rmiqui A, Rodriguez-Cabezas MN, Orduña A, Rodriguez-Torres A, Osuna A. Comparative sensitivity of six serological tests and diagnostic value of ELISA using purified antigen in hydatidosis. *J Clin Lab Anal* 2001;15:14-8.
- Sayek I, Onat D. Diagnosis and treatment of uncomplicated hydatid cyst of the liver. *World J Surg* 2001;25:21-7.
- Varshney M, Shahid M, Maheshwari V, Mohammed Azfar Siddiqui, Siddiqui MA, Alam K, Mubeen A, et al. Hydatid cyst in tail of pancreas. *BMJ Case Rep* 2011;2011:bcr0320114027.
- Karaman B, Battal B, Ustunsoz B, Ugurel MS. Percutaneous treatment of a primary pancreatic hydatid cyst using a catheterization technique. *Korean J Radiol* 2012;13:232-6.
- Motie MR, Rezapana A, Pezeshki Rad M, Razavian H, Azadmand A, Khajeh M. Primary Localization of a Hydatid Cyst in the Latissimus Dorsi Muscle: An Unusual Location. *Surg Infect (Larchmt)* 2011;12:401-3.
- Besim H, Karayalçın K, Hamamci O, Güngör C, Korkmaz A. Scolicidal agents in hydatid cyst surgery. *HPB Surg* 1998;10:347-51.