

Rapid Successful Management of Diffuse Alveolar Hemorrhage as the Primary Presentation of Chlorine Gas Inhalation: A Rare Case Report

Mohsen Yaghubi¹, Morteza Valaei², Reza Ghasemi³, Mahmood Hosseinzadeh Maleki⁴, Sara Rezaei⁵, Samaneh Kakhki⁶

¹ Department of Extra-Corporeal Circulation (ECC), Razavi Hospital, Imam Reza International University, Mashhad, Iran

² Department of Internal Medicine, Razavi Hospital, Imam Reza International University, Mashhad, Iran

³ Department of Cardiology, 9 Dey Educational Hospital, Torbat Heydariyeh University of Medical Sciences, Torbat Heydariyeh, Iran

⁴ Department of Cardiac Surgery, Imam Reza Hospital, Mashhad University of Medical Sciences, Mashhad, Iran

⁵ Department of Cardiology, Faculty of Medicine, Mashhad University of Medical Sciences, Mashhad, Iran

⁶ Department of Clinical Biochemistry, School of Paramedical Sciences, Torbat Heydariyeh University of Medical Sciences, Torbat Heydariyeh, Iran

Received: 11 Feb. 2021; Accepted: 01 Sep. 2021

Abstract- Chlorine-containing bleach, as a common disinfectant, can cause mild to severe symptoms from nasal irritation to life-threatening conditions such as acute respiratory distress syndrome (ARDS). However, the toxicity level of chlorine gas depends on the duration and concentration of exposure. Herein, we describe the case of a 44-year-old man admitted to the emergency department with a chief complaint of severe shortness of breathing and hemoptysis following accidental, short-time exposure to chlorine-containing bleach. Because of the life-threatening condition, he was transferred to the Intensive Care Unit (ICU) and received mechanical ventilation along with a corticosteroid agent and antibiotic therapy. Despite limited data on management of the severe complications of the exposure, the patient successfully recovered after four days.

© 2021 Tehran University of Medical Sciences. All rights reserved.

Acta Med Iran 2021;59(10):617-620.

Keywords: Diffuse alveolar hemorrhage (DAH); Acute respiratory distress syndrome (ARDS); Chlorine gas inhalation; Corticosteroids

Introduction

The cleaning agent of chlorine-containing bleach is widely used as a safe detergent for household consumption (1). If inhaled, this irritant gas could also damage the eyes, skin, gastrointestinal tract, cardiovascular system, and especially respiratory system (2).

The major problems after exposure to a chlorine-containing bleach are respiratory complications, including rhinitis, pneumonitis, pulmonary edema, and also acute respiratory distress syndrome (ARDS) that are almost life-threatening without rapid and appropriate management (3-5).

In the current report, we describe the case of a middle-aged man exposed to chlorine gas for a short time, resulting in ARDS and diffuse alveolar hemorrhage (DAH).

Case Report

A 44-year-old man was admitted to the emergency department (ED) complaining of severe shortness of breathing and hemoptysis. About 6 hours before admission to our hospital, he had cleaned his car's window with chlorine-containing bleach and exposed it to chlorine gas for about 2-3 min within his completely enclosed car. Despite a short time of exposure, he had experienced shortness of breathing with a sudden onset and crescendo pattern. He reported a smoking history of 20 cigarettes per day for about 15 years, no history of addiction and substance abuse.

In spite of suffering from anemia and goiter, he had not received any medication or hospitalization before admission. His hemodynamic parameters were found to be in critical ranges as follows: blood pressure 90/45 mmHg, heart rate 138 bpm, respiratory rate 38

Corresponding Author: S. Kakhki

Department of Clinical Biochemistry, School of Paramedical Sciences, Torbat Heydariyeh University of Medical Sciences, Torbat Heydariyeh, Iran
Tel: +98 9155186014, Fax: +98 5152226010, E-mail address: samane_ph@yahoo.com

Copyright © 2021 Tehran University of Medical Sciences. Published by Tehran University of Medical Sciences

This work is licensed under a Creative Commons Attribution-NonCommercial 4.0 International license (<https://creativecommons.org/licenses/by-nc/4.0/>). Non-commercial uses of the work are permitted, provided the original work is properly cited

Diffuse alveolar hemorrhage following chlorine-containing bleach inhalation

breath/min, and oxygen saturation 78% at rest. He was also in a febrile state with a central temperature of 38.6° C. The primary physical examinations were revealed bilateral crackles in both the upper and lower of the chest in auscultation. The oral test showed no significant irritation. Moreover, other examination results were found to be normal. Due to these critical situations, the patient was immediately transferred to the intensive care unit (ICU), treated with high-flow oxygen therapy through a nasal high flow, and tested instantly for the arterial blood gas (ABG). ABG showed a severe acute respiratory acidosis with pH=6.97, PCO₂=98, HCO₃⁻=27, O₂ sat=55%, and PaO₂=32 mmHg.

For these reasons as well as increasing of respiratory effort, hemoptysis, and airway obstruction (and therefore decreasing in clearing secretions' ability) during fifteen minutes, he was prepared to initiate invasive mechanical ventilation. Accordingly, endotracheal intubation was performed. Mechanical ventilation mode was volume/assisted-controlled with auto-flow regulator (PRVC mode), and fentanyl infusion 50-100 mcg/h as prescribed by the anesthesiologist.

The portable anteroposterior chest radiography was emergently taken, which showed a significant diffused bilateral infiltration, especially in upper lobes, indicating no evidence of cardiovascular involvement caused by pulmonary disorders. Moreover, costophrenic angles were sharp with no symptoms of pleural effusion. Tracheal had been shifted to the right side that could be due to enlargement of the thyroid gland, as found from the primary history-taking (Figure 1). Due to the lack of accurate microbiological evidence, the broad-spectrum antibiotics, such as meropenem (1 g q6h) and ciprofloxacin (400 mg q8h) were prescribed. In addition, the corticosteroid agent of methylprednisolone (40 mg q6h) was administered through intravenous infusion. Based on the patient's febrile state at the time of arrival to the ED, the BACTEC blood and urine cultures were taken which their results were negative.

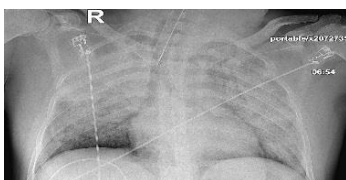


Figure 1. Chest x-ray in AP view demonstrated diffuse bilateral infiltration, especially in upper lobes, without any evidence of pleural effusion

Because of the severe hemoptysis, the following recommended laboratory tests were requested to achieve

a differential diagnosis. The urinary analysis showed blood, protein, and glucose with two-plus weight, a few bacteria, and granular casts. In the hormone assay, a moderate risk of sepsis with procalcitonin of 1.34 ng/mL was found. Other hormonal assessments based on probable thyroid disorder showed a thyroid-stimulating hormone (TSH) of 1.67 μ IU/mL and a free T4 of 0.92 ng/dL. The hematological assessment on the first day revealed the normal parameters as follows: hemoglobin=13.5 g/dL, hematocrit=46.6%, and microcytosis and hypochromic anemia (mean corpuscular volume=57.9 fL and mean corpuscular hemoglobin=16.8 p.g). In addition, fibrinogen, fibrinogen degradation product (FDP), and erythrocyte sedimentation rate was specified to be 260 mg/dL, 5<FDP<20, and 2 mm/h, respectively. All biochemistry test results were normal, except for blood sugar (374 mg/dL) and hs-CRP (14.39 mg/L).

Coagulation test results were also normal and were as follows: prothrombin time 13.0 s, partial thromboplastin time 27.9 s, and international normalized ratio 1.00. However, D-dimer quantitative was found to be in the high range (3665 ng/FEU mL), according to which the cardiac consultation was performed. Both purified protein derivation (PPD) test (1 mm; after 48 h of incubation) as a serologic assessment and coombs wright test were negative. Based on the rheumatologic and inflammatory studies, immunoassay tests showed negative results for cytoplasmic anti-neutrophil cytoplasmic antibodies (C-ANCA), perinuclear anti-neutrophil cytoplasmic antibodies (P-ANCA), anti-cyclic citrullinated peptide (anti-CCP), and antinuclear antibodies (ANA). Moreover, the native double-stranded DNA antibody (Anti-dsDNA) had a normal range (9.51 IU/mL). Besides, transthoracic echocardiography revealed a normal ejection fraction (about 55%; eye estimation). Other complications such as pericardial effusion were rejected. No evidence for a regional wall motion abnormality and significant valvular heart disease was found. The mean of pulmonary artery pressure was in the upper limits of the normal (19 mmHg). Moreover, electrocardiographic parameters, including sinus tachycardia, narrow complex tachycardia, P-wave pulmonale, P-R interval, and QTc interval, were normal.

The chest high-resolution computed tomography was taken without using contrast. The results revealed significant ground-glass opacities with interlobular septal thickening in both lungs -more prominent in bilateral upper lobes. However, no pleural effusion was observed. The tracheal was shifted to the right side, and no significant pathological mediastinal lymphadenopathy

was found (Figure 2). The radiologist recommended pulmonary hemorrhage. The patient was then scheduled for bedside fiberoptic bronchoscopy. Bronchoalveolar lavage (BAL) during bronchoscopy was carried out, and the obtained specimen was sent for the bacterial, fungal, viral, and pneumocystis carinii cultures. The results showed hemosiderosis deposition in alveoli.

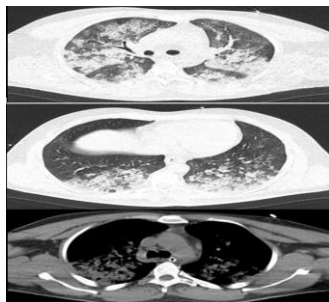


Figure 2. Chest high-resolution computed tomography (HRCT), without contrast, in an inspiration period and different views, showed interlobular septal thickening and also bronchiectasis in both lungs more prominent in bilateral upper lobes that revealed pulmonary hemorrhage

On the second day of ICU admission, a significant decline in hemoglobin and hematocrit levels was observed (Hgb=7.4 g/dL and Hct=24.9%). Therefore, a single unit of the iso-group and iso-Rh packed red cells was transfused. Instantly, the patient was assessed for probable gastrointestinal bleeding as a source of the severe decline of hemoglobin level, by which no gastrointestinal evidence was confirmed. According to the clinical presentation and para-clinical documents, especially after BAL (demonstrating the existence of hemosiderosis in the alveolus), the patient was approached to alveolar hemorrhage as a definitive diagnosis. Therefore, the primary interventions, such as mechanical ventilation and corticosteroid therapy were continued; however, methylprednisolone was tapered. Antibiotics were also reduced and then discontinued.

On the fourth day, the ventilatory and ABG parameters were found to be in an acceptable range. Therefore, after mechanical ventilation (for 80 h), the patient weaned (2 h) and extubated completely. A follow-up chest x-ray showed significant decrease in the bilateral opacities (Figure 3). On the fifth and sixth days, the patient was only treated by the supplemental oxygen therapy using a simple face mask, followed by a nasal cannula with a flow of 3 L/min. Then he was transferred to the post-ICU with a good general condition. Two days later, he was discharged and advised to follow his anemic situation and avoid exposure to any pulmonary-irritating agent.

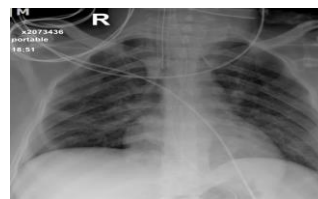


Figure 3. Chest x-ray in AP view after mechanical ventilation weaning demonstrated the significant improvement in diffuse opacities of both lungs

Discussion

Chlorine-based agents are extensively used in homes and industries. However, inhalation of chlorine gas at high levels (≥ 15 ppm) can cause mild to severe respiratory problems such as ARDS (6). Diffuse alveolar hemorrhage (DAH) is a prominent clinicopathologic syndrome of pulmonary hemorrhage that arises from the alveolar capillaries, arterioles, and venules in pulmonary microcirculation (7). The clinical manifestations of DAH are hemoptysis, anemia, diffuse lung infiltration, and acute respiratory failure (8).

In this report, we presented a case of DAH following a short-term exposure (3 min) to a chlorine-containing bleach, whose syndrome was proved by clinical and para-clinical assessments, including hemoptysis, an acute drop in hemoglobin, and new infiltrates on chest x-ray. Other symptoms, including fever, acute severe respiratory distress, tachycardia, and bronchial breath sounds, were also observed (9,10). In addition, we found a febrile state with ARDS presentation, tachycardia, bilateral crackles in the upper and lower chest as the less prevalent symptoms. The mentioned clinical symptoms can confirm the rarity of the case.

This rare case was successfully treated with a combination therapy protocol including mechanical ventilation and corticosteroid agent (40 mg q6h). In fact, treatment for chlorine inhalation in humans is largely supportive with some medical interventions, and mechanical ventilation is rarely used for ARDS originated from inhalation of chlorine-based agents (2), which may take 5 to 7 days (11). The appropriate therapeutic management with supportive care as well as corticosteroid agent diminished the severe respiratory reaction against the chlorine, which in turn led to rapid resolving of the life-threatening symptoms and extubating of the patient within four days.

The severity of chlorine inhalation injury strongly depends on the exposure duration, gas concentration, ventilation time, and case susceptibility. Although a long-time exposure to such compound can cause severe respiratory reactions, *e.g.*, DAH (12), our patient showed

Diffuse alveolar hemorrhage following chlorine-containing bleach inhalation

serious complications (*i.e.*, both DAH and ARDS) with a rapid progression during only a short-time exposure. The degree of pulmonary injury in patients with exposure to chlorine gas is also influenced by pre-existing airway hyperresponsiveness (4), which in our case it was probably induced by a long smoking history. It seems that there is a correlation between smoking and complications of chlorine inhalation; however, its precise mechanism is still unknown (2).

The rapid and successful treatment of the case by above-mentioned procedure, (despite the fact that complications in DAH cases may last for several weeks) is clinically interesting. Generally, administration of corticosteroids for DAH treatment is controversial; while these drugs showed a positive effect in pulmonary function recovery in animals immediately after chlorine exposure (13), no improvement in the respiratory function and resolving the clinical complications in human has been reported yet (14). This study, therefore, highlighted a very effective intravenous infusion of methylprednisolone (low dose of corticosteroid) in treatment of such cases. It is worth to note that a rapid diagnosis of DAH and instant providing a supportive respiratory care remain fundamental in managing the patients. In addition, bronchoscopy and BAL should be alternately assessed during the treatment period, as they play a critical role in evaluation of these cases (10).

Co-occurrence of ARDS and DAH caused by a short-time exposure to the chlorine gas is rare. Besides, patients with toxic gas inhalation are routinely managed by the supportive care. In the present case, ARDS and DAH presentations were successfully treated with a low dose of methyl prednisolone, as a corticosterid, in combination with supportive care. Therefore, a precise treatment can decrease the morbidity and mortality rates associated with the mentioned complications. However, early recognition and accurate diagnosis are pivotal in such effective treatment.

Acknowledgments

The authors would like to thank all nurses from the general ICU, Razavi Hospital, Mashhad, Iran.

References

1. Shin HJ, Chang JS, Ahn S, Kim TO, Park CK, Lim JH, et al. Acute respiratory distress syndrome and chemical burns

- after exposure to chlorine-containing bleach: a case report. *J Thorac Dis* 2017;9:E17-20.
2. Babu RV, Cardenas Jr V, Sharma G. Acute respiratory distress syndrome from chlorine inhalation during a swimming pool accident: a case report and review of the literature. *J Intensive Care Med* 2008;23:275-80.
3. Parimon T, Kanne JP, Pierson DJ. Acute inhalation injury with evidence of diffuse bronchiolitis following chlorine gas exposure at a swimming pool. *Respir Care* 2004;49:291-4.
4. Mapp C, Pozzato V, Pavoni V, Gritti G. Severe asthma and ARDS triggered by acute short-term exposure to commonly used cleaning detergents. *Eur Respir J* 2000;16:570-2.
5. Wang L, Wu D, Wang J. Chlorine gas inhalation manifesting with severe acute respiratory distress syndrome successfully treated by high-volume hemofiltration: a case report. *Medicine (Baltimore)* 2018;97:e11708.
6. White CW, Martin JG. Chlorine gas inhalation: human clinical evidence of toxicity and experience in animal models. *Proc Am Thorac Soc* 2010;7:257-63.
7. Park MS. Diffuse alveolar hemorrhage. *Tuberc Respir Dis (Seoul)* 2013;74:151-62.
8. Baumgartner M, Ashton R. Diffuse alveolar hemorrhage. *South Med J* 2011;104:274-5.
9. Shen M, Zeng X, Tian X, Zhang F, Zeng X, Zhang X, et al. Diffuse alveolar hemorrhage in systemic lupus erythematosus: a retrospective study in China. *Lupus* 2010;19:1326-30.
10. Abdalla AO, Al-Khafaji J, Akella PM, Taha M. A fatal case of diffuse alveolar hemorrhage as the initial presentation of systemic lupus erythematosus: A case report and literature review. *Respir Med Case Rep* 2018;24:55-7.
11. Schönhofer B, Voshaar T, Köhler D. Long-term lung sequelae following accidental chlorine gas exposure. *Respiration* 1996;63:155-9.
12. Lara AR, Schwarz MI. Diffuse alveolar hemorrhage. *Chest* 2010;137:1164-71.
13. Bosse GM. Nebulized sodium bicarbonate in the treatment of chlorine gas inhalation. *J Toxicol Clin Toxicol* 1994;32:233-41.
14. Chester EH, KaimaL PJ, Payne Jr CB, Kohn PM. Pulmonary injury following exposure to chlorine gas: possible beneficial effects of steroid treatment. *Chest* 1977;72:247-50.