

# Arhinia and Bilateral Anophthalmia: Report of a Rare Case and Review of Literature

Goli Golpayegani<sup>1</sup>, Mehrdad Jafari<sup>2</sup>, Anita Karimi<sup>3</sup>

<sup>1</sup> Otorhinolaryngology Research Center, Tehran University of Medical Sciences, Tehran, Iran

<sup>2</sup> Otorhinolaryngology Research Center, Imam Khomeini Hospital Complex, Tehran University of Medical Sciences, Tehran, Iran

<sup>3</sup> Shahid Beheshti Medical University, Tehran, Iran

Received: 14 Feb. 2021; Accepted: 21 Aug. 2021

**Abstract-** Arhinia is an extremely rare condition reported in less than 100 cases so far. We report a case of arhinia with bilateral anophthalmia. In physical examination, only alar portions of the nose were partially formed. No septal, lower, upper lateral cartilages or nasal bones were detectable. Both nostrils were atretic. The orbital area was covered with skin, and eyebrows were partially formed. Bilateral complete cleft lip and palate were evident. Surgical interventions should be considered not only for reconstruction of the external nose but for timely creation of a lacrimal passage and repair of the accompanying cleft lip and palate.

© 2021 Tehran University of Medical Sciences. All rights reserved.

*Acta Med Iran* 2021;59(10):621-624.

**Keywords:** Arhinia; Anophthalmia; Cleft lip

## Introduction

Arhinia (congenital absence of the nose) is an extremely rare condition. It has been reported in less than 100 cases in the literature so far and is often accompanied by somatic anomalies, including ocular and midline defects (1). Arhinia may predispose the patient to severe respiratory and feeding problems at birth, mandating early intervention (2-4). Its most severe presentation is called Bosma Arhinia Microphthalmia Syndrome (BAMS) (MIM 603457) and encompasses arhinia, microphthalmia, and hypogonadotropic hypogonadism (5) and was first described by Bosma in 1981 (6).

Herein, we report a case of arhinia with bilateral anophthalmia.

## Clinical Report

A 2-month-old male infant presented to a tertiary referral hospital with features of arhinia, bilateral anophthalmia, and complete bilateral cleft lip and palate. He was delivered at full term, and his birth weight was 2700 grams. Parents were not relatives, and the mother claimed not to have taken any medications during her

pregnancy. Both parents were completely healthy without any known exposure to environmental toxins. The mother refused her obstetrician's advice to take fetal ultrasounds or genetic screenings during pregnancy due to her low economic state. The patient had two healthy siblings, and no significant family history was mentioned by his parents.

In the primary physical examination, only alar portions of the nose were partially formed, with no septal, lower, and upper lateral cartilages or nasal bones were detectable on palpation. Both nostrils were atretic. The orbital area was covered with skin, and eyebrows were partially formed. Bilateral complete cleft lip and palate were evident, forcing the patient to be fed by a nasogastric tube. In the systemic examination, no other abnormal finding was noticed apart from the aforementioned anomalies (Figure 1).

The ultrasound revealed normal testes, bladder, and urinary tracts. A brain CT scan was obtained, which demonstrated bilateral anophthalmia, absent nasal bones, anomalous ventricles, and agenesis of the corpus callosum (Figure 2A, 2B).

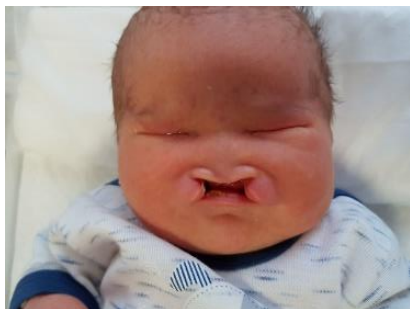**Corresponding Author:** M. Jafari

Otorhinolaryngology Research Center, Imam Khomeini Hospital Complex, Tehran University of Medical Sciences, Tehran, Iran  
Tel: +98 2166581628, Fax: +98 2166581628, E-mail address: Mehrdadj82@yahoo.com

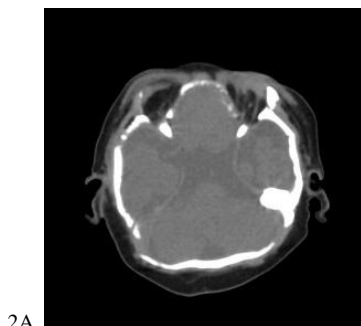
Copyright © 2021 Tehran University of Medical Sciences. Published by Tehran University of Medical Sciences

This work is licensed under a Creative Commons Attribution-NonCommercial 4.0 International license (<https://creativecommons.org/licenses/by-nc/4.0/>). Non-commercial uses of the work are permitted, provided the original work is properly cited

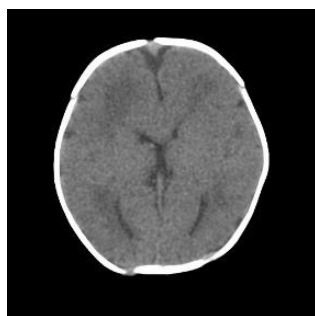
## Arhinia and bilateral anophthalmia



**Figure 1.** Clinical picture of the patient with arhinia, bilateral anophthalmia, and cleft lip and palate



2A.



2B.

**Figure 2.** Brain CT scan of the patient

Comprehensive blood tests including complete blood count, blood urea nitrogen, creatinine, arterial blood gases, albumin, thyroid stimulating hormone (TSH), insulin growth factor (IGF) and glucose level were run and returned normal.

Chromosomal analysis revealed a normal 46, XY karyotype.

The parents decided to discharge the patient after three days and allowed no further investigations. Later in a follow-up call, he was sadly reported to be dead a few days after discharge due to a septic-like presentation.

## Review of literature

### Embryology

Arhinia is presumed to result from a failure of the development of nasal placodes between the third and the tenth gestational weeks (7).

*The upper lip and main nasal structures:* The medial nasal prominences merge with the frontal processes and form the midline structures including the upper lip, philtrum, columella, cartilaginous septum and nasal bones.

*The secondary palate:* The frontal and maxillary processes also fuse and result in the formation of the palatal shelves at 10<sup>th</sup> week of gestation. After 4 weeks, these shelves merge into the septum and form the secondary palate.

*The nasal alae:* The lateral and medial nasal processes merge together and result in the formation of the nasal alae (3).

Therefore, a defective process or an early fusion may result in a cleft lip, cleft palate and nasal deformities concurrently as seen in our patient.

### Etiology

The exact pathogenesis of arhinia is poorly understood, but some genetic etiologies have been postulated, including a gain-of-function mutation in SMCHD1 (8). Interestingly, a loss-of-function mutation results in a completely different condition called Facioscapulohumeral Muscular Dystrophy 2. Treacher Collins Syndrome is also reported in some cases (9,10).

The karyotype of patients is often normal whenever obtained. However, a chromosome 3-12 translocation and anomalies in chromosome 9 have been reported in a few cases.

Of note, the antenatal history is often uneventful (2), but gestational diabetes, polyhydramnios, and fever were also reported (4,11,12).

### Diagnosis

Arhinia is often diagnosed after birth. However, there are reports of prenatal diagnosis as early as the 23<sup>rd</sup> gestational week by MRI (13). Ultrasound screening may be of help by revealing a flat profile of the fetus (4,9,12).

### Presentation

Arhinia is commonly associated with orbital and midfacial defects. The orbital manifestations include microphthalmia/anophthalmia, choroidal and palpebral colobomas, cataracts, and hypertelorism with palpebral fissures slanting down (14-17). The absence of nasolacrimal ducts is another feature that can result in sight impairment by the overproduction of tears (1,14,18,19).

A cleft palate or high-arched palate is also a common finding (2,15,17). Auricular anomalies sometimes accompany arhinia, most commonly presented as low-set

ears (2,19,20). Brain anomalies have been reported (2), and an absent olfactory bulb is another noticeable finding on MRI of some cases (15,17).

Hypogonadism is a feature of Bosma syndrome, which can result in decreased bone density and reduced quality of life<sup>15</sup>. Therefore, screening hypogonadotropic hypogonadism in patients with arhinia can be helpful. Of note, reproductive function in these patients is usually decreased and rarely normal (21).

### Treatment

Due to the rarity of the disorder, there exists no single best surgical treatment. A wide variety of surgical interventions have been reported, including placement of a nasal prosthesis (18,19) or nasal reconstruction with maxillary osteotomies and local flaps (9,10,22).

Some accompanying anomalies are also addressed surgically. Contrary to the common belief that newborns are obligate nasal breathers, there are reports of patients who were able to breathe on their own at birth without any intervention (9,10,22,23). However, an oral airway or a tracheostomy tube is sometimes mandatory (2-4,16,17). Dacryocystorhinostomy is another procedure that is sometimes essential in order to prevent teary eyes and subsequent eyesight problems (14,18).

We present a patient with arhinia, bilateral anophthalmia and cleft lip and palate. Airway management is extremely important upon delivery in these patients and although not all cases require an intervention, the physician should be prepared for the management of a respiratory distress immediately after birth. Surgical interventions should be considered not only for reconstruction of the external nose, but for timely creation of a lacrimal passage and repair of the accompanying cleft lip and palate in order to prevent further complications.

### Acknowledgements

The authors would like to thank Dr. Fatemeh Hajjoui for her helpful assistance with the radiologic evaluation of this case.

### References

- Fuller AK, McCrary HC, Graham ME, Skirko JR. The Case of the Missing Nose: Congenital Arhinia Case Presentation and Management Recommendations. *Ann Otol Rhinol Laryngol* 2020;129:645-8.
- Akkuzu G, Akkuzu B, Aydin E, Derbent M, Ozluoglu L. Congenital partial arhinia: a case report. *J Med Case Rep* 2007;1:97.
- Albernaz VS, Castillo M, Mukherji SK, Ihmeidan IH. Congenital arhinia. *AJNR Am J Neuroradiol* 1996;17:1312-14.
- Cusick W, Sullivan C, Rojas B, Poole A, Poole D. Prenatal diagnosis of total arhinia. *Ultrasound Obstet Gynecol* 2000;15:259-61.
- Graham Jr JM, Lee J. Bosma arhinia microphthalmia syndrome. *Am J Med Genet A* 2006;140:189-93.
- Bosma J, Henkin R, Christiansen R, Herdt J. Hypoplasia of the nose and eyes, hyposmia, hypogeusia, and hypogonadotropic hypogonadism in two males. *J Craniofac Genet Dev Biol* 1981;1:153-84.
- Mondal U, Prasad R. Congenital arhinia: a rare case report and review of the literature. *Indian J Otolaryngol Head Neck Surg* 2016;68:537-9.
- Gordon CT, Xue S, Yigit G, Filali H, Chen K, Rosin N, et al. De novo mutations in SMCHD1 cause Bosma arhinia microphthalmia syndrome and abrogate nasal development. *Nat Genet* 2017;49:249-55.
- Cesaretti C, Gentilin B, Bianchi V, Melloni G, Bonaguro M, Rossi C, et al. Occurrence of complete arhinia in two siblings with a clinical picture of Treacher Collins syndrome negative for TCOF1, POLR1D, and POLR1C mutations. *Clin Dysmorphol* 2011;20:229-31.
- Brusati R, Donati V, Marelli S, Ferrari M. Management of a case of arhinia. *J Plast Reconstr Aesthet Surg* 2009;62:e206-e10.
- Alansari H, Fawzi A, Alshaikh R, Althawadi N, Janahi W, Alsaad I. Congenital Arhinia. *Bahrain Med Bull* 2018;40:251-3.
- Qiang Z, Jin-zhi P, Quan L. Congenital arhinia of fetus: a case report. *Tianjin Med J* 2019;47:754.
- Li X, Zhang L, Wang F. Prenatal diagnosis of total arhinia by MRI. *Jpn J Radiol* 2015;33:672-4.
- Ali MJ, Singh S, Naik MN. Image-guided lacrimal drainage surgery in congenital arhinia-microphthalmia syndrome. *Orbit* 2017;36:137-43.
- Brasseur B, Martin CM, Cayci Z, Burmeister L, Schimmenti LA. Bosma arhinia microphthalmia syndrome: clinical report and review of the literature. *Am J Med Genet A* 2016;170:1302-7.
- Courtney J, McCabe J, Craig S. Congenital arhinia. *Arch Dis Child Fetal Neonatal Ed* 2014;99:F75.
- Feledy JA, Goodman CM, Taylor T, Stal S, Smith B, Hollier L. Vertical facial distraction in the treatment of arhinia. *Plast Reconstr Surg* 2004;113:2061-6.
- Fernandes N, Van den Heever J, Sykes L, Kluge H. Nasal reconstruction of a patient with complete congenital arhinia: a clinical report. *J Prosthet Dent* 2016;116:924-7.
- Goossens I, Kemp P, Bredell M, Sykes LM. Implant

## Arhinia and bilateral anophthalmia

- retained nasal prosthesis for a child with congenital arhinia-a case report. *SADJ* 2008;63:390-2.
20. Becerra-Solano LE, Chacón L, Morales-Mata D, Zenteno JC, Ramírez-Dueñas ML, García-Ortiz JE. Bosma arhinia microphthalmia syndrome in a Mexican patient with a molecular analysis of PAX6. *Clin Dysmorphol* 2016;25:12-5.
  21. Delaney A, Volochayev R, Meader B, Lee J, Almpani K, Noukelak GY, et al. Insight Into the Ontogeny of GnRH Neurons From Patients Born Without a Nose. *J Clin Endocrinol Metab* 2020;105:1538-51.
  22. Abulezz T. Congenital heminasal aplasia: clinical picture, radiological findings, and follow-up after early surgical intervention. *J Craniofac Surg* 2019;30:e199-202.
  23. Altuntas Z, Uyar I, Yildirim MEC. A Rare Congenital Facial Abnormality: Complete Arhinia. *Facial Plast Surg* 2021;37:274.