

**INDICATION FOR OPERATIVE TREATMENT OF
ANGIOMATA OF THE BRAIN.**

N. O. Ameli *

In intracranial aneurysms poor prognosis and high operation mortality and morbidity are the major reasons for many discussions and papers on the subject. The opposite is true for angiomata. Two examples out of many will be sufficient.

1. A boy of 12 was admitted to the Queen Elizabeth Hospital (Birm) Neurosurgical Department in November 1948. The day before admission he had sustained a slight head injury. On admission he was semi comatose with slight hemiparesis. Through a temporal burr hole a temporal lobe hematoma was aspirated. Angiogram at a later date revealed a small arterio-venous angioma. Fig. 1. Operation for this angioma has been refused. The patient 15 years after this incident is quite well.

2. A boy of 14 was admitted to Pahlavi Hospital in June 1955, four hours after falling off his bicycle. Three hours after the accident he suddenly lost consciousness.

On admission he was deeply comatose with neck rigidity and positive Kernings sign. Lumbar puncture gave a heavily blood stained C.S.F. His condition gradually improved but he had a right hemiplegia and aphasia.

Angiogram (Fig. 2.), demonstrated a left parietal arterio-venous angioma. Operation for removal of this angioma was refused. Patient is doing well at school and has had no further trouble, although he is still hemiparitic.

Having had many similar cases that have not suffered any further inconvenience, we have nevertheless operated on 12 cases in the last 14 years. In this paper, the reasons for removal of the angioma in these 12 cases are briefly discussed.

* Professor of Neurosurgery, Pahlavi Hospital, Tehran University - Iran.

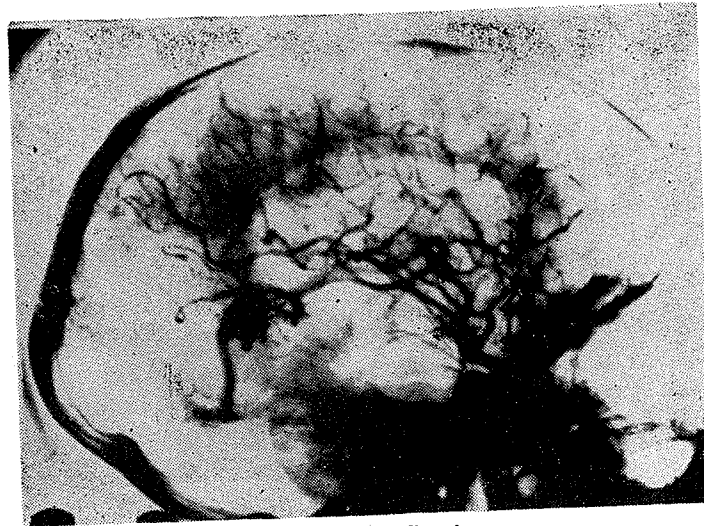


Fig 1
Small arterio venous angioma. Post-traumatic haematoma aspirated.
Patient well after 17 years.

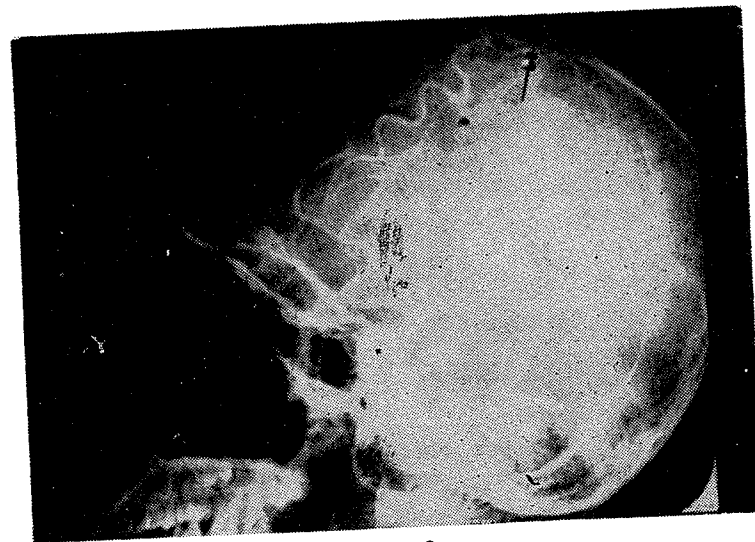


Fig 2
Post-traumatic subarachnoid haemorrhage. Left sided angioma. No
operation. Patient well after 8 years.

It is felt that there are four indications for operative removal of these malformations.

1. In the course of evacuation of an intracerebral hematoma.
2. Repeated hemorrhages. (More than one).
3. Progressive deterioration in patient's condition.
4. Uncontrollable epilepsy.

Two reasons are often given as prophylactic treatment of removal of angiomata. One for danger of Cardiac strain, and the other danger of hemorrhage. Statistics and follow up of the known cases does not uphold this view.

In the following table, (Fig, 3) the indications for operation in 12 cases are given. It is thought, when there is a clear indication for operation, size and position of the angioma should not deter the surgeon.

All the patients were in the young age group, 9 — 25. There were 8 males to 4 females. There were 10 supratentorial and 3 infratentorial angiomata.

Two cases had a small aneurysmal sac protruding into a cavity in the brain, the site of an absorbed hematoma. Both these patients had repeated hemorrhages. We have operated on one case of sturge Webber syndrome, because of uncontrolled epilepsy and gradual mental deterioration.

3 cases had more than one indication for operation. In five cases the angioma was removed in the course of evacuation of hematoma.

Five cases for uncontrolled epilepsy.

Two for repeated hemorrhage.

Three for progressive deterioration in the clinical condition.

There was no mortality.

Now few examples will be given.

A man of 22 was admitted to Pahlavi Hospital in January 1957 with six years history of Jacksonian fits affecting the right side of the body with increasing right hemipareses.

Angiogram revealed a large left parietal arterio-venous angioma. (Fig. 4). Because of the position and size of the lesion., operation was not considered. Six months later the patient returned with severe deterioration

Brain Angiomata

Age	Sex	Type	Loc. in	1/2 in.	1/4 in.	1/8 in.	1/16 in.	1/32 in.	1/64 in.	Op.	Result
15	F	Small	R. Temp.	+	-	-	-	-	-	Remov.	R
20	M	Small	R. Temp.	+	-	-	-	-	-	Remov.	R
23	M	Large	L. Pari.	-	-	+	+	+	+	Rem.	R
18	M	Large	R. Pari.	-	+	-	-	+	+	Remov.	R
17	M	Large	R. Pari.	-	-	-	-	+	+	Remov.	R
7	F	Small	R. Temp.	+	-	-	-	-	-	Remov.	R
21	F	Small	L. Pari.	-	+	-	-	+	+	Rem.	R
25	M	Car.	L. Pari.	+	-	-	-	-	-	Rem.	R
8	M	Small	R. Temp.	+	-	-	-	-	-	Rem.	R
22	M	Small	L. Pari.	-	+	-	-	+	+	Remov.	R
10	F	Small	R. Pari.	-	-	-	-	+	+	Remov.	R
22	M	Large	R. Pari.	-	-	-	-	-	-	Remov.	R
25	M	Large	R. Pari.	-	-	-	-	-	-	Remov.	R
12	M	Large	R. Pari.	-	-	-	-	-	-	Remov.	R
12	M	Large	R. Pari.	-	-	-	-	-	-	Remov.	R
12	M	Large	R. Pari.	-	-	-	-	-	-	Remov.	R

Fig 3

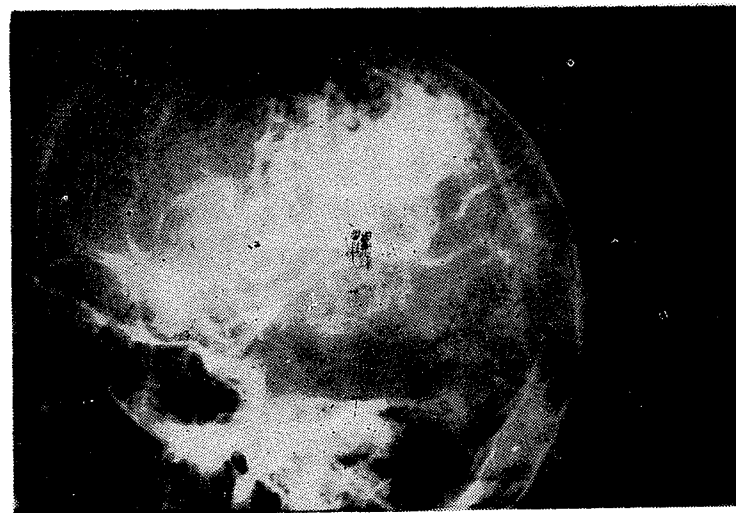


Fig 4

Large left sided angioma. Operation carried out because of continuous deterioration of the patient's condition. Angioma completely removed. Full but slow recovery.

in hemipareses, mental condition and speech. Fits were uncontrollable. Patient had been threatening to commit suicide.

Under hypotension the angioma was completely removed. For three weeks he was aphasic and hemiplegic, but he gradually improved and is now leading a useful life.

In all the cases where there had been previous hemorrhage the angiomas were situated in the wall of cavity filled with colorless or xanthochromic fluid.

As already mentioned two cases had a small aneurysmal sac.

In one after two hemorrhages patient had typical temporal lobe epileptic attacks which were uncontrollable. Angiogram, Fig. 5, revealed a small arteriovenous malformation in the left temporal lobe. At operation, fig. 6, aneurysm was protruding into the cavity covered by a thin layer of white matter. The angioma was completely removed. There was no post operative dysphasia or hemianopsia, and the condition has remained excellent with no fits.

Another case, Fig. 7 his angioma seemed to be in an inaccessible position, but as he had had two hemorrhages, and was hemiparetic, he was operated on.

Post-operatively he has completely recovered from his hemipareses but has had two fits in the last eight months, so we had to increase his medication. Otherwise he is leading a normal life.

Two of our cases were in the posterior fossa. In one case patient had a delayed post-traumatic intracerebella hematoma and on the same side of his tongue there was also a large arterio-venous angioma. (Fig. 8)

The other had progressive cerebellar signs, with headache, vomiting and papilloedema.

A carotid angiogram demonstrated a tumour in the posterior fossa, we made an erroneous diagnosis of a meningioma. At operation we were confronted with a large anterior-venous malformation.

We thought that the decompression may help the patient. His condition gradually deteriorated. A vertebral angiogram demonstrated the size of this malformation. At a second operation we clipped many of the vessels (arteries ?) in the periphery of the mass. There was a definite shrinkage of the angioma. It was decided to remove the whole mass in a third operation. After the second operation patient very much improved, and discharged himself. We are still awaiting his return. (Fig 9)

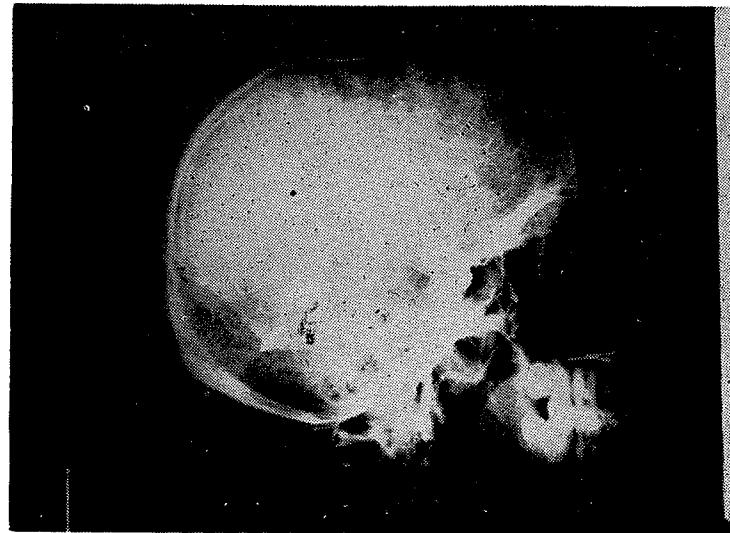


Fig 5

Small temporal arterio venous aneurysm giving rise to two attacks of subarachnoid haemorrhage and temporal epilepsy.




Fig 6

Small aneurysmal dilatation presenting in a cavity which was filled with xanthochromic fluid.

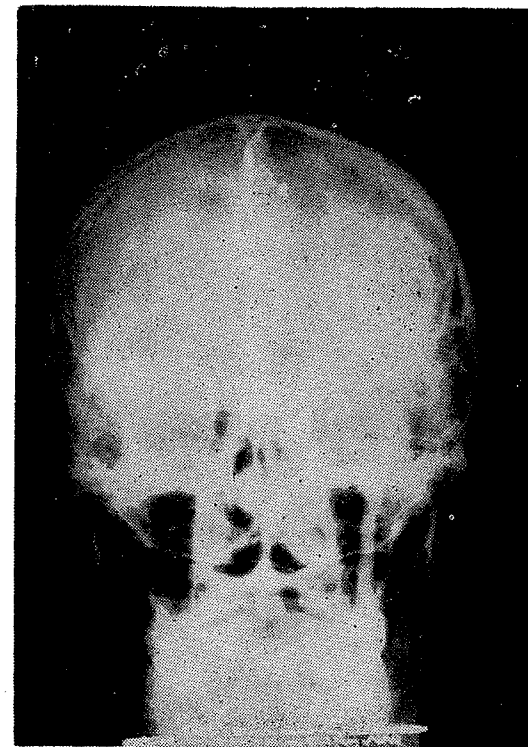

Fig 7

Small parasagittal aneurysmal dilatation of an arteriovenous malformation giving rise to two attacks of subarachnoid haemorrhage. This was in a small cavity and was easily removed.

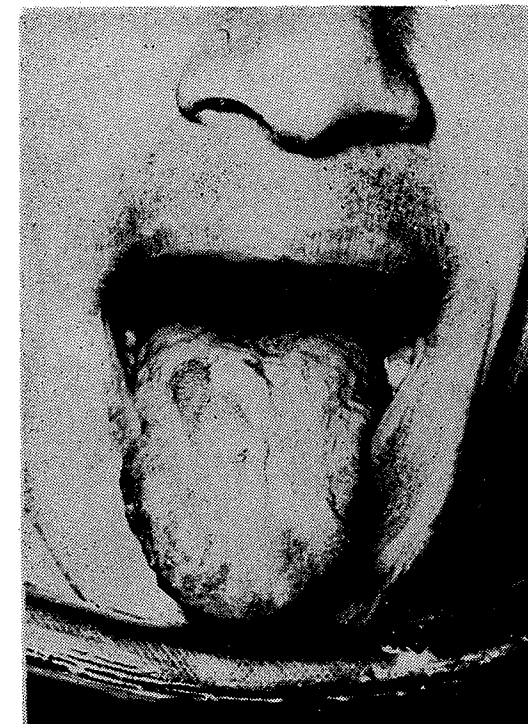


Fig 8

Angioma of Tongue associated with cerebral angioma on the same side.

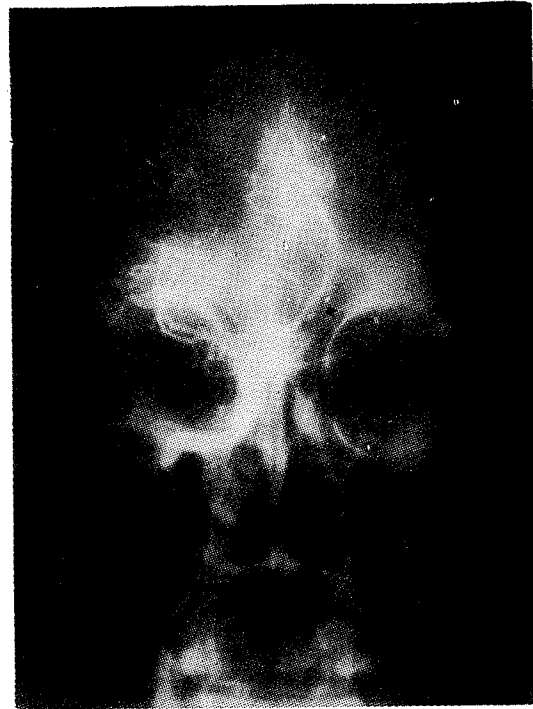


Fig 9 A large posterior fossa arteriovenous angioma.

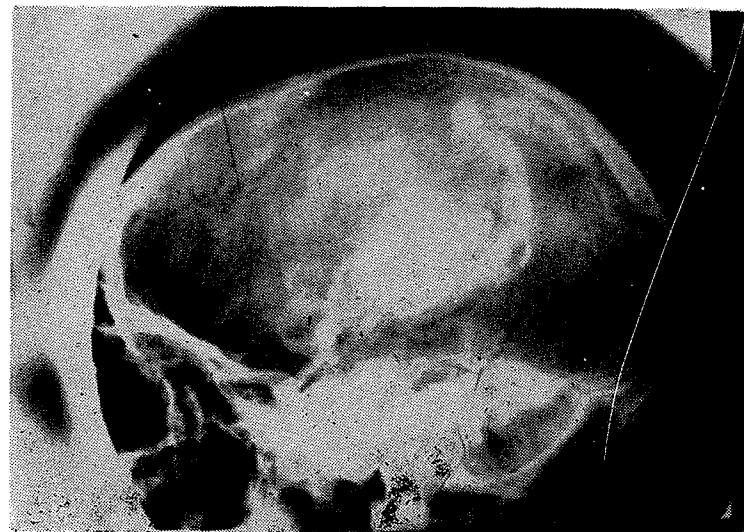

Fig 10

Arterio-venous angioma, demonstrating the feeding artery: angioma proper and the larger vein from the angioma to the sagittal sinus.

Summary and Conclusion.

Many patients with known angiomata of the brain lead a useful life, and unless it is proved that their life is threatened, or their capacity for work progressively diminishing, do not need removal of the angiomata.

In the course of removal of an intracranial hematoma the angioma should be removed if identified. At such a time the removal is easy as the vessels are collapsed.

When there is a definite indication for operation, the size and position of the angioma should not deter the surgeon.

Besides and adequate surgical technique, one should utilise all the modern facilities, e.g. hypothermia, hypotension, rapid transfusion and temporary occlusion of main arteries.

With proper care the results of operation are gratifying.

Résumé et Conclusion

Beaucoup de malades avec angiome connu du cerveau menent une vie utile. Sauf dans le cas où leur vie est menacée, ou la capacité de leur travail est diminuée, aucune intervention sur l'angiome est nécessaire.

Pendant l'évacuation d'un hématorne intracérébral, si l'angiome est identifié il devrait être enlevé ceci est d'autant plus facile que les vaisseaux sont collabés.

Quand l'indication opératoire est formelle le volume ou la localisation de l'angiome ne doit pas troubler le neurochirurgien. Outre la technique opératoire, les facilités modernes, comme l'hypothermie et l'hypotension, ainsi que les transfusions rapides et la ligature provisoire des grosses artères devraient être utilisés. Avec les précautions d'usages, les résultats opératoires sont satisfaisants.