

Perianal Plasmocanthoma After BCG-Immunotherapy: Case Report and Review of Literature

Masoumeh Roohaninasab^{1,4*}, Azadeh Goodarzi^{1,4*}, Reza Chalangari², Katalin Martits-Chalangari², Nazgol-Sadat Haddadi³, Parvin Mansouri⁴

¹ Department of Dermatology, Rasool Akram Medical Complex Clinical Research Development Center (RCRDC), Iran University of Medical Sciences, Tehran, Iran

² Kassir Dermatology, Dallas, Texas, USA

³ Experimental Medicine Research Center, School of Medicine, Tehran University of Medical Sciences, Tehran, Iran

⁴ Department of Dermatology, Skin and Stem Cell Research Center, Tehran University of Medical Sciences, Tehran, Iran

Received: 02 Oct. 2021; Accepted: 14 May 2022

Abstract- Plasmocanthoma is a rare verrucous tumor classified as a form of reactive plasmacytosis. We present the first reported case of plasmocanthoma following exposure to bacillus Calmette-Guérin (BCG) and a comprehensive review of the literature to better illustrate the patients' characteristics and proposed risk factors, clinical features, diagnosis, treatment, and outcome of current reports. A 64-year-old female presented with a perianal hyperkeratotic plaque and diffused inflammatory macerated erosions in the intergluteal cleft and adjacent to the plaque after intravesical BCG immunotherapy. Laboratory studies disclosed systemic abnormalities and local infection or malignancies. Biopsy showed intradermal polyclonal plasma cell infiltration with acanthosis. The lesions were successfully treated with carbon dioxide laser ablation followed by the combination of pulsed dye laser and intralesional corticosteroid. Diagnosis of cutaneous reactive plasmacytosis should be confirmed by excluding the systemic causes of plasmacytosis and malignancies. It responds well to intralesional corticosteroids; however, in severe cases and large sizes, other treatments such as carbon dioxide laser ablation and pulsed dye laser should be considered as a combined therapy. Identification of causative factors is impractical while skin irritants with subsequent inflammation seem to be involved; as in the current report, BCG contact with skin initialized the pathologic process.

© 2022 Tehran University of Medical Sciences. All rights reserved.

Acta Med Iran 2022;60(6):375-381.

Keywords: Plasmocanthoma; Reactive plasmacytosis; Bacillus calmette-guérin (BCG); Plasma cell; Mucocutaneous; BCG-immunotherapy

Introduction

Reactive plasma cell proliferation is a benign immunologic reaction to known (infection, friction, trauma, etc.) and unknown stimuli that present as a heterogeneous spectrum of mucocutaneous and cutaneous disorders. It is characterized by infiltration and proliferation of polyclonal mature plasma cells in the skin and mucosal or orificial areas (oral, upper airway, or genital mucosa) that typically present as

severe hyperemia, erosions, or lobulated warty lesions (1). The disease had been reported under a wide variety of names depending on the involved mucosa (2) since 1986 when White *et al.*, classified this group of similar disorders involving different body sites under the nomenclature of "plasma cell mucositis" (3). However, there are reports of plasmacytosis involving the skin exclusively. Thus, a recent classification has categorized these disorders into mucous plasmacytosis, mucocutaneous plasmacytosis, cutaneous plasmacytosis, and plasmocanthoma (4).

Corresponding Author: P. Mansouri

Department of Dermatology, Skin and Stem Cell Research Center, Tehran University of Medical Sciences, Tehran, Iran
Tel: +98 2126151500, Fax: +98 2142910703, E-mail addresses: Mansorip@sina.tums.ac.ir, mansouripr@yahoo.com

*M. Roohaninasab and A. Goodarzi contributed equally to this work.

Copyright © 2022 Tehran University of Medical Sciences. Published by Tehran University of Medical Sciences

This work is licensed under a Creative Commons Attribution-NonCommercial 4.0 International license (<https://creativecommons.org/licenses/by-nc/4.0/>). Non-commercial uses of the work are permitted, provided the original work is properly cited

Perianal plasmocanthoma after BCG-immunotherap

Plasmocanthoma is an extremely rare verrucous tumoral mass defined by dense dermal plasma cell infiltrate and psoriasiform changes in the epidermis. It has been reported to involve the oral mucosa, particularly oral commissures and the perianal area (4,5). The differential diagnosis of perianal involvement includes fungal (candida granuloma), bacterial (chlamydia, syphilis, and leishmania) or viral infections (HPV), squamous cell carcinoma, lichen planus, cicatricial pemphigoid, allergic or contact dermatitis, extramedullary plasmacytoma, sarcoidosis, plasma cell granuloma and inflammatory bowel disease (IBD).

In this report, we present a 64-year-old woman with perianal plasmocanthoma developed after bacillus Calmette-Guérin (BCG) immunotherapy of non-invasive bladder cancer. Furthermore, we review the pertinent medical literature for plasmocanthoma. This review outlines our current understanding of the clinical presentation of plasmocanthoma, the pathophysiology of this disorder, and currently available approaches to diagnosis and management.

Case Report

A 64-year-old female with a history of non-muscle invasive bladder cancer (NMIBC) presented to the dermatology clinic with rapidly progressive erosions and protruding lesions involving the intergluteal cleft and perianal area accompanied by a burning and itching sensation. It had started with small erosions and papules in the perianal area one month after completion of a 6-session course of BCG immunotherapy for bladder cancer. Over the period of one month, the size and number of lesions rapidly increased, and they were fused to form a protuberant plaque in the perianal area with the formation of erosions around it. The erosions also spread to the intergluteal cleft. She was heterosexual and did not have any history of atopy. She was a non-smoker and had never consumed alcohol. Her previous medical history revealed NMIBC, which was diagnosed three months prior to the development of lesions and had been successfully treated with intravesical BCG immunotherapy. She had not received any other medications or treatment for the lesions, including topical corticosteroid, antibacterial, or antifungal creams.

A clinical examination revealed an ill-defined, macerated, erythematous, hyperkeratotic verrucous plaque in the perianal area. Cracking of the perianal lesion was also noticed. Diffused inflammatory macerated erosions were found in the intergluteal cleft

and adjacent to the perianal lesion (Figure 1). Regional lymph nodes were not enlarged, and other systemic examinations were all normal. The complete blood counts, serum biochemistry, and ESR were all within the normal limits. There was also no proteinuria.

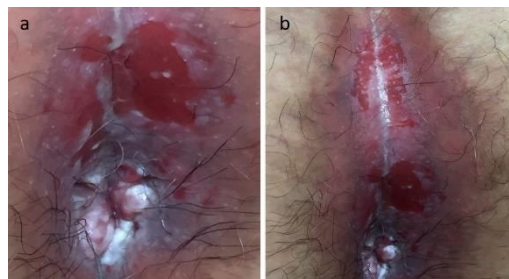

Figure 1. Clinical appearances of the lesions before treatment. a) Perianal vegetative lesion surrounded with erosions; b) Diffused inflammatory macerated erosions in the intergluteal cleft

Considering the clinical hypothesis of leishmaniasis, syphilis, and viral or fungal infections, we performed Montenegro's intradermal reaction tests, VDRL, Giemsa or Gram's-stained tissue smears, acid-fast staining, fungal and bacterial culture of biopsy specimen including mycobacterial culture, polymerase chain reaction and Potassium hydroxide (KOH) mounts which were all negative. Assaying of *Treponema pallidum* hemagglutination and human immunodeficiency virus were also negative. Interestingly, diffused edema of the rectum was detected during the colonoscopy. The histopathologic findings of rectal mucosa biopsy showed mild chronic inflammatory reaction without atypia.

Histopathological examination of the specimen from the perianal lesion revealed focal parakeratosis containing neutrophilic aggregation at the surface, large area loss of the epidermis leading to ulceration, and irregular acanthosis of the epidermis. There were extensive areas of elongated rete-ridges and effacement dermo-epidermal junction with the saw-tooth pattern. The upper dermis revealed densely band-like infiltration of plasma cells with some lymphocytes, scattered eosinophils, and small aggregation of neutrophils throughout the papillary and reticular dermis. Immunostaining for kappa and lambda light chains showed a polyclonal population of plasma cells. We observed no signs of neoplasia or inflammation of smooth muscle in deeper tissue (Figure 2).

Typical mucocutaneous lesions and histopathologic properties established the diagnosis of plasm acanthoma. The verrucous lesion was first removed with carbon dioxide (CO₂; Union Medical Engineering Co., Seoul, South Korea; surgical mode, UM-L25) laser ablation.

Then, the patient received three sessions of pulsed dye laser (PDL; *Chromogenex*, UK; vascular mode, 585 nm, pulse width 450 μ sec) followed by an intralesional injection of triamcinolone acetonide (40mg/session) four weeks apart. The lesions healed completely after the third session of therapy, and there were no complications or recurrences during one year of follow-up (Figure 3).

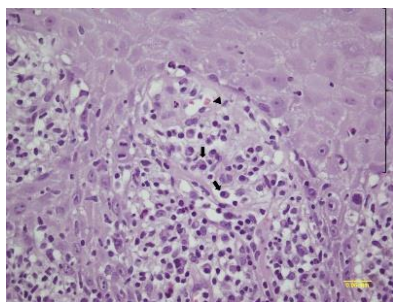


Figure 2. Dense mature plasma cell infiltration (arrows) beneath the acanthotic and hyperkeratotic epidermis (brace) overlying an elevated and polypoid tumoral structure. Russel bodies also are seen (head arrow) (hematoxylin and eosin stain; $\times 400$)

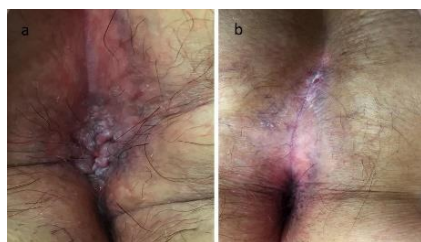

Figure 3. Clinical appearances of the lesions after the last session of treatment. a) Perianal area; b) intergluteal cleft

Discussion

This report shows the first case of plasm acanthoma developed following the BCG immunotherapy of bladder cancer. This presentation could be really challenging for clinicians. The current patient presented with an erythematous and hyperkeratotic perianal plaque with diffused inflammatory erosions in the intergluteal cleft. Interestingly, the biopsy of lesions showed numerous polyclonal plasma cells in the epidermis and dermo-epidermal interface with marked acanthosis. We performed a comprehensive assessment to rule out other causes of dermal plasma cell infiltrations, including extramedullary or primary cutaneous plasmacytoma, lichen planus, cicatricial pemphigoid, sarcoidosis, IBD, or infections (e.g., syphilis, HPV and candida granuloma) by distinct clinical features and proper laboratory examinations. Unlike candida granuloma, our patient was old rather than in early childhood, and there

was no histopathologic evidence of granuloma, which excluded the possibility of BCG or candida-induced granuloma. The normal CBC, biochemistry tests, and lack of proteinuria excluded the diagnosis of extramedullary plasmacytoma. In addition, the absence of vesiculation, pruritus, and previous history of atopy ruled out the presence of allergic contact dermatitis. There was also no evidence of anaplasia, granuloma, multinucleated giant cells, or prominent neutrophil infiltration in histopathologic evaluations. After negative screening results of all possible etiologies, the diagnosis of plasm acanthoma was confirmed.

Plasm acanthoma is a subset of reactive plasma cell proliferation disorders characterized by benign dermal infiltration of polyclonal mature plasma cells (1). The etiology of reactive plasmacytosis, including plasm acanthoma, is obscure while it has been suggested to be a nonspecific reactive inflammatory response to allergens or exogenous agents, including insect bite, trauma, chronic irritation, Candida infection, subclinical infections secondary to low levels of serum and secretory IgA, poor hygiene and moisture (6,7). In addition, the influence of T cells and macrophages on B cell growth and differentiation has been reported to be associated with plasma cell cheilitis (8).

We did not find any evidence of any fungal infection in tissue smears, and the patient's hygiene was acceptable. We assumed that the BCG immunotherapy would be the most probable causative factor in our case. Adjuvant intravesical BCG immunotherapy, a suspension of live attenuated *Mycobacterium Bovis bacilli*, is the treatment of choice for NMIBC (9). However, it sometimes is associated with various local side effects (chemical and bacterial cystitis, urinary frequency and incontinence, hematuria, granulomatous prostatitis, epididymo-orchitis, ureteral obstruction, and scar tissue in the bladder) and systemic side effects (fevers, sepsis, general malaise, systemic BCG reactions, allergic reactions, and BCG induced lung infection and liver toxicity) (10). There are also reports of cutaneous complications of BCG immunotherapy, including generalized skin rash, ulceration, and formation of draining abscesses at the sites of injection and anaphylactic purpura (11). F Kureshi *et al.*, reported BCG-related granuloma reaction in a 69-year-old man who presented with ulceration at the base of the penis and papules involving the glans penis with inguinal lymphadenopathy one month after injection of intravesical BCG. Unlike our case, the biopsy findings revealed granulomatous inflammation with foci of dermal necrosis, while the staining and tissue cultures

Perianal plasmocanthoma after BCG-immunotherap

were negative (12). A cutaneous plasma cell tumor has been reported to develop at a site of injury and inflammation where modified BCG was given intradermally as an adjunctive treatment for a patient with lymphoma (13). BCG is a strong Th1 response-inducing adjuvant; however, it could also stimulate the

humoral immunity (13). We can then assume that in our patient, injury due to complicated intravesical BCG may have given rise to an abnormal polyclonal reactive process.

We have reviewed all the previously reported plasm acanthoma cases before February 2019 (Table 1).

Table 1. Literature review (1960-2019) of plasm acanthoma

Authors	Publication Year	Age/ Gender	Site	The course of the clinical presentation and findings	Proposed causative agent	Histopathologic findings	Treatment	Clinical course after treatment	Outcome
J. Ferreira-Marques (14)	1962	46/ M	Upper lip	A vegetating hyperkeratotic nodule	Insect bite	Acanthosis, hyperkeratosis dense infiltrate of plasmocytes	Excision	Complete response	
Ramos E et al., (15)	1965	29/F	Upper lip	A verrucous sharply demarcated tumor	Injury by bird beak	Acanthosis, hyperkeratosis dense infiltrate of plasmocytes	Radiation therapy	N/A	N/A
Goring HD et al., (16)	1985	N/A	The right angle of the mouth	N/A	Candidal infection	N/A	N/A	N/A	N/A
Kerkhof et al., (5)	1995	80/F	Platinum molle	Indolent soft verrucous tumor	Plasma cell cheilitis	Acanthosis, marked papillomatosis, dense dermal infiltrate of plasma cells and T-lymphocytes	No treatment	-	-
M Senol et al., (4)	2008	46/ M	Perianal area, intertriginous areas: toe-webs, groins, prepuceum, perineum, umbilicus, oral commissures, right gingivobuccal mucosa	Verrucous, macerated, and hyperkeratotic perianal mass + heavy inflammation, maceration, and fissures of intertriginous areas and gingivobuccal mucosa	-	Acanthosis, elongated rete ridges, dense dermal infiltrate of plasmacells with some neutrophils and lymphocytes Immunohistochemistry: Positivity for kappa and lambda light chains	Excision of the perianal tumor, daily oral 60 mg prednisolone for 2 weeks. The therapy ceased within one month with weekly 10 mg decreases. Topical corticosteroid, intralesional corticosteroid, topical calcineurin inhibitor	Complete response	no recurrence during 1 year of follow-up
HS Roh et al., (17)	2013	73/ M	Both angles of the mouth	Asymptomatic, verrucous, erythematous, scaly plaques	Candidal infection	Exophytic plaque with dense dermal infiltrates of plasma cells, few lymphocytes, and histiocytes. Hyperkeratosis, acanthosis, elongation of rete ridges, pseudoepitheliomatous hyperplasia Immunohistochemistry: Positivity for kappa and lambda light chains	CO2 laser ablation	No effect	Complete response No recurrence during 3 months of follow up

Cont. table 1

G Khatri et al., (18)	2014	80/F	Lips and oral cavity (gingiva, palate, and buccal mucosa)	Initially started with a painful ulcer and papules on the lips Evolved to fleshy, verrucous, skin-colored plaque involving the lips and oral cavity with swelling, fissuring, and crusting of the lips Small necrotic ulcer on the buccal mucosa Enlarged cervical and submandibular lymph nodes	Poor orodental hygiene	Ulcerated epidermis, dense dermal plasma cell infiltrate, focal neutrophilic exocytosis	Two sessions of intralesional triamcinolone acetate (40mg/session)	Marked improvement after 3 weeks and finally a complete response	No recurrence during 2 years of follow up
BB Braga et al., (19)	2016	40/F	Lower lip	Two flares up 7 years apart: lobulated warty lesion	-	Dense plasma cell infiltrate in the entire superficial dermis, epidermis thickening, elongation of the rete ridges, eosinophilic bodies, exocytosis of lymphocytes Immunohistochemistry: positivity for kappa, lambda and CD 138	The first flare-up disappeared spontaneously. Second flare up: three sessions of intralesional triamcinolone acetate (20mg/session) Carbon dioxide (CO2) laser ablation followed by three sessions of pulsed dye laser combined with intralesional triamcinolone acetate (40 mg/session)	Complete response	no recurrence during 6 months of follow up
Our case	2019	64/F	Perianal area, intergluteal region	Ill-defined, macerated, erythematous, and hyperkeratotic verrucous cracking plaque in the perianal area Macerated erosions in the intergluteal cleft and adjacent to the plaque	BCG immunotherapy	Acanthosis, ulcerated epidermis, elongated rete-ridges, dense plasma cell infiltration in the upper dermis, few lymphocytes, eosinophils, and neutrophils Immunohistochemistry: Positivity for kappa and lambda light chains		Complete response	No recurrence during one year of follow up

M; male, F; female, N/A; not available

The medical databases PubMed (National Library of Medicine, Bethesda, Maryland, USA) and Google Scholar searched for the “plasm acanthoma” keyword. Furthermore, a few non-English articles were retrieved through a manual search using the reference list of accessible publications. We found 10 papers, each reporting almost one case; however, we excluded two papers as they were not related to the subject. Among the nine patients identified (including the current case), three were males, and five were females, while the gender of one case was not available. The mean age of patients was 57.25 years (range: 29-80 years).

Various clinical presentations of plasm acanthoma

have been reported, but it mostly appears as a verrucous polypoid tumoral mass, commonly found in oral mucosa, especially at the angle of mouth and lips (14-19). It may also involve buccal mucosa, palatum, perianal region, periumbilical area, finger webs, or inguinal areas (4,5,18). It may initially be started with painful ulcers and papules on lips and then evolve into fleshy, verrucous, skin-colored plaques with swelling, fissuring, and crusting lesions (18). Furthermore, it could be an indolent, asymptomatic, verrucous scaly plaque at the mouth angles or palatum (5,17). Small necrotic ulcers on the buccal mucosa and inflamed, macerated fissures of oral commissures may also be

present (4,18). The perianal area has been reported to be affected as an ill-defined, verrucous, macerated, and hyperkeratotic perianal mass (4,5). Symptoms are also variable, from no pain (5,17) and indolent course to intense pain (18), itch, and burning sensation. The regional lymph nodes could be enlarged (18) or normal (4), while enlarged lymph nodes are more in favor of other diagnoses.

Injury and irritation following insect bite (14), bird beak (15) and complicated intravesical BCG immunotherapy, Candidial infections (16,17), and poor hygiene (18) have been proposed as causative agents of plasmocanthoma. There is also a report of co-occurrence of plasmocanthoma with plasma cell cheilitis signifying them to be a spectrum of the same disease (5).

The principal histologic features are acanthosis, hyperkeratosis with dense dermal infiltrate of polyclonal plasma cells characterized by positive kappa and lambda light chains, and CD 138 in immunohistochemistry analysis (19). The epithelial changes include papillomatosis (5), elongated rete ridges (4,17,19), pseudoepitheliomatous hyperplasia¹⁷, ulcerations, and erosions (18). In addition to plasma cells, the presence of immune cells related to a nonspecific inflammatory response, such as dense or little infiltration of T-lymphocytes (4,5,17,19), histiocytes (17), neutrophils (4,18) and eosinophilic bodies (19) have been reported. Ulcerations and erosions are usually with an acute nonspecific secondary inflammation (18).

Topical, intralesional, and systemic corticosteroids, topical calcineurin inhibitors, excision or destructive procedures (CO₂ laser ablation), and radiation therapy have been applied as therapeutic modalities with inconsistent success (17). In an indolent asymptomatic case, no treatment was applied without the development of any serious complications (5). We tried CO₂ laser ablation, which failed to resolve the lesion completely. Subsequently, we, for the first time, used the combination of PDL laser and intralesional corticosteroid for the treatment of plasmocanthoma with satisfactory results. PDL emits visible light that is absorbed by oxyhemoglobins in blood vessels which results in the destruction of specific tissues. Interestingly, PDL has been reported to be used for treating inflammatory skin diseases, presumably by inducing the production of specific cytokines that alleviate inflammation (20).

The long-term prognosis of patients with reactive plasma cell proliferation disorders is generally good. There is no report of progression to a malignancy up to

date (7). There is also one report of spontaneous improvement of plasmocanthoma; however, it has recurred after 7 years (19). There is no recurrence or serious complication with plasmocanthoma after treatment by the current reports, while none of them has had a long-term follow-up of more than 2 years (18). We did not also observe any recurrence in a follow-up of the one-year period.

In conclusion, mucocutaneous reactive plasmacytosis, especially plasmocanthoma, has been rarely reported in the dermatology literature. The pathophysiology, risk factors, clinical presentations, the best form of therapy, and prognosis of this group of disorders are almost unknown. The discrepancy in the nomenclature even makes the diagnosis more complicated. The diagnostic and therapeutic approach thus could be challenging for dermatologists. Excluding the systemic involvement that may occur in a minor subset of patients should be a priority, while identification of promoting factors is almost impossible or uncertain.

Acknowledgments

The authors would like to thank Rasool Akram Medical Complex Clinical Research Development Center (RCRDC) and Mrs Farahnaz Nikkhah for the technical and editorial assistance.

References

1. James WD, Berger TG, Elston DM. Disorders of the mucous membranes: Plasma cell cheilitis, plasmocanthoma. In: James WD BT, Elston DM, ed. *Andrews' Diseases of the Skin*. Philadelphia: Elsevier Saunders; 2011:785.
2. Rocha N, Mota F, Horta M, Lima O, Massa A, Sanches M. Plasma cell cheilitis. *J Eur Acad Dermatol Venereol*2004;18:96-8.
3. White JW, Olsen KD, Banks PM. Plasma cell orificial mucositis: report of a case and review of the literature. *Arch Dermatol* 1986;122:1321-4.
4. Senol M, Ozcan A, Aydin NE, Hazneci E, Turan N. Intertriginous plasmacytosis with plasmocanthoma: report of a typical case and review of the literature. *Int J Dermatol* 2008;47:265-8.
5. Van de Kerkhof P, Van Baar H. Co-occurrence of plasma cell orificial mucositis and plasmocanthoma. Report of a case and review of the literature. *Dermatology*. 1995;191:52-5.
6. Curto CR, Chaves MY, Morán AG, Asensio PG, López

- G. Plasma cell gingivitis. *Cutis* 2002;69:41-5.
7. Bharti R, Smith DR. Mucous membrane plasmacytosis: a case report and review of the literature. *Dermatol Online J* 2003;9:15.
 8. Aiba S, Tagami H. Immunoglobulin- producing cells in plasma cell orificial mucositis. *J Cutan Pathol* 1989;16:207-10.
 9. Doyle E, Crew J, Mostafid H, Tuthill M, Cerundolo V, Gerristen W, et al. Urothelial cancer: a narrative review of the role of novel immuno- therapeutic agents with particular reference to the management of non- muscle invasive disease. *BJU Int* 2019;123:947-58.
 10. Garcia C, Jina H, Bergersen P, Chalasani V. Bladder Contracture—A Rare and Serious Side Effect of Intravesical Bacillus Calmette-Guérin Therapy. *Urol Case Rep* 2016;4:22-4.
 11. Hirayama T, Matsumoto K, Tsuboi T, Fujita T, Satoh T, Iwamura M, et al. Anaphylactoid purpura after intravesical therapy using bacillus Calmette-Guerin for superficial bladder cancer. *Hinyokika kiyo* 2008;54:127-9.
 12. Kureshi F, Kalaaji AN, Halvorson L, Pittelkow MR, Davis MD. Cutaneous complications of intravesical treatments for bladder cancer: granulomatous inflammation of the penis following BCG therapy and penile gangrene following mitomycin therapy. *J Am Acad Dermatol* 2006;55:328-31.
 13. Suster S, Ronnen M, Huszar M, Pines A, Schibi-Brilliant G. Induction of cutaneous plasma cell tumor as a complication of adjuvant immunotherapy with methanol extraction residue of bacillus Calmette-Guerin. *Oncology* 1987;44:279-82.
 14. Ferreira-Marques J. Beitrag zur Kenntnis der Plasmocytosis circumorificialis (Schuermann)“Plasmoakanthoma”. *Arch Klin Exp Dermatol* 1962;215:151-64.
 15. Ramos ESJ. Das Plasmoakanthoma. *Hautarzt*. 1965;16:7-11.
 16. Göring H, Linse R, Jäger K, Raschke N. Plasmoacanthoma. A contribution to the diagnosis, etiopathogenesis and nosology. *Z Hautkr* 1985;60:884-96.
 17. Roh HS, Jeong MG, Choi WJ, Jue MS, Ko JY, Ro YS. Plasmoacanthomas at both angles of mouth treated with carbon dioxide laser ablation. *J Dermat* 2013;40:217-9.
 18. Khatri G, Mahajan VK, Chauhan PS, Mehta KS, Chander B, Gupta M. Plasmoacanthoma of oral cavity and plasma cell cheilitis: two sides of same disorder “oral plasma cell mucositis”? *Our Dermatol Online* 2014;5:172.
 19. Braga BB, Michalany AO, Oliveira Filho Jd, Cucé LC. Plasmoacanthoma. *An Bras Dermatol* 2016;91:128-30.
 20. Mamalis A, Ho D, Parsi KK, Jagdeo J. Successful Treatment of Actinic Granuloma With Pulsed-Dye Laser and Fractionated Carbon Dioxide Laser. *Dermatol Surg* 2018;44:452-4.